

Nervus olfactorius

Nervus olfactorius (**I. cranial nerve** , **olfactory nerve**) is referred to as a *false* cranial nerve, it is a paired set of fibers formed bilaterally by the axons of olfactory cells originating from the pars olfactoria of the nasal mucosa. It arises as an outgrowth of the telencephalon . It has no cores and does not branch.

Course of the olfactory nerve

It is formed by unmyelinated central projections (*fila olfactoria*) of olfactory cells, which are located in *the regio olfactoria* of the mucous membrane of the nasal cavity. The dendrites extending from the olfactory cells are spherically expanded at the ends, and several cilia extend from this expansion into the mucus layer on the surface of the mucous membrane. Odor substances soluble in water or in mucus **bind to receptors** on the surface of the **cilia**. This causes irritation and nerve impulses are conducted to **the olfactory bulb** (*bulbus olfactorius*).

The projections of the olfactory cells form a **plexus** from which *the olfactory nerves* emerge . These penetrate the openings in *the lamina cribrosa* ossis ethmoidalis and sink into the right and left *bulbus olfactorius* . Inside the bulb, it branches and ends on the dendrites of the mitral cells. **Mitral cells** serve to conduct olfactory signals through the olfactory pathway to the primary olfactory cortex area (*paleocortex* , *pyriform cortex* , *entorhinal cortex*)

 For more information see *Olfactory track*.

Disorders of the olfactory nerve

- **Hyposmia** - partial loss of smell;
- **anosmia** - complete loss of smell;
- **hyperosmia** - excessive sensitivity;
- **parosmia** - qualitative disorder.

 For more information see *Olfactory disorders*.

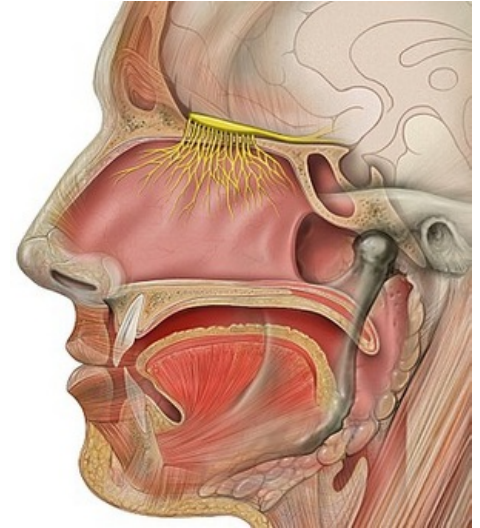
Links

Related Articles

- Smell and taste
- Cranial nerve outputs
- Smell disorders

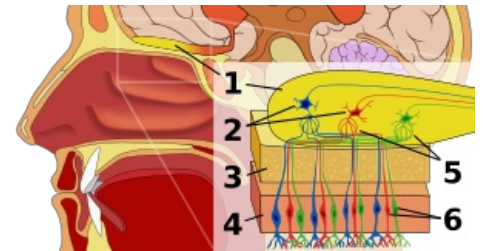
References

- PETROVICKÝ, Pavel, et al. *Anatomie s topografií a klinickými aplikacemi III. -- Neuroanatomie, smyslová ústrojí a kůže*. 1. edition. 2002. ISBN 80-8063-048-8.
- GRIM, Miloš - DRUGA, Rastislav. *Základy anatomie, Periferní nervový systém, smyslové orgány a kůže*. 1. edition. Praha : Galén, 2014. 173 pp. ISBN 978-80-7492-156-8.



Olfactory nerve

FACING	A14.2.01.004
Function	transmission of olfactory information to the brain
Distance from	telencephala
Branches	doesn't have
Image of polio	hyposmie, anosmie, hyperosmie, parosmie



1. Bulbus olfactorius 2. Mitral cells 3. Lamina cribrosa 4. Mucous membrane of the nasal cavity 5. Synapse 6. Fila olfactoria

Cranial nerves

Olfactory nerve • Optic nerve • Oculomotor nerve • Trochlear nerve • Trigeminal nerve • Abductor nerve • Facial nerve • Vestibulocochlear nerve • Glossopharyngeal nerve • Vagus nerve • Accessory nerve • Hypoglossal nerve

Portal: Anatomy

▪