

Pelvis

The pelvis is formed by the union of the two **pelvic bones** and the **sacral bone**. It creates a limited space in which some abdominal organs are stored. It is a bone structure that shows significant **sex differences** (the female pelvis is adapted for childbirth).

Bone base

Os sacrum

It has the shape of a four-sided pyramid, **basis ossis sacri** turns cranially to the lower surface of the last lumbar vertebra, caudally directs **apex ossis sacri** and connects to the coccyx. The lateral sides form **facies auriculares** to connect with the hip bones.

The front surface (*facies pelvina*) is **concave**, four transverse *lineae transversae* run across it (at the point of fusion of the sacral vertebrae), on the sides there are four pairs of openings (*foramina sacralia ventralia*), through which the anterior branches of the sacral nerves emerge. The dorsal surface is **convex**, there is the *foramina sacralia dorsalia* for the exit of the posterior branches of the sacral nerves. In the middle of the dorsal side there is the **canalis sacralis**, which opens in the area of the apex as the *hiatus canalis sacralis*, where the last sacral and coccygeal nerves emerge.

Between the *basis ossis sacri* and the front surface, a rounded edge emerges (**promontorium**), from which the **linea terminalis** extends laterally, delimiting the entrance to small pangs.

Os coxae

The pelvic bone is formed by the fusion of three paired bones (right and left) – the ilium, ischii and pubis.

Os ilium

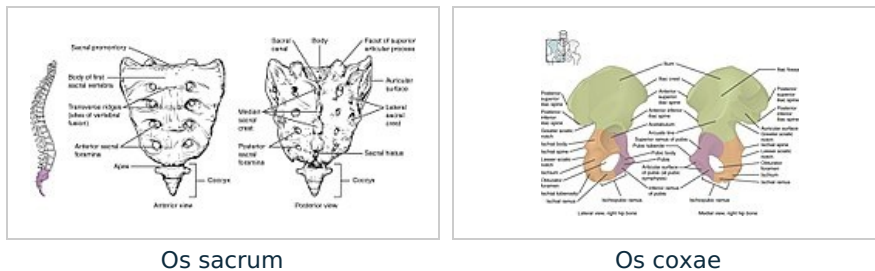
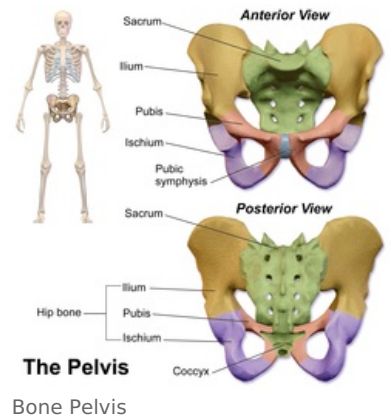
Formed by the body (*corpus*) and the blade (*ala ossis ilium*). Cranially there is a well palpable **crista iliaca**, ventrally there is also a palpable spine (*spina iliaca anterior superior*), dorsally the spine is less prominent (*spina iliaca posterior superior*). Medially there is the *facies auriculares* to connect with the *os sacrum*. The inner surface is deepened in a flattened pit (**fossa iliaca**), which forms the bottom of the abdominal cavity. Caudally there is an arc-shaped **linea arcuata** (part of the linea terminalis). The outer surface of the shovel is covered by the gluteal muscles.

Ischial axis

It consists of a body (*corpus*), a shoulder (*ramus ossis ischii*) and a massive ischial hump (*tuber ischiadicum*). On the dorsal side, it extends into a sharp spine (*spina ischiadica*). The cranial part (*pars pubica*) is **connected to the pubic bone** and forms part of the boundary of the *foramen obturatum*.

Os pubis

Formed by the body (*corpus*) and the shoulder (*ramus ossis pubis*). Together with the bone ischial axis, it forms the boundary of the *foramen obturatum*. Medially there is a roughened surface (**facies symphysis**) to which the cartilage of the symphysis grows, connecting the two bones together. Above it we find a bump (*tuberculum pubicum*) from which extends a sharp edge (*pecten ossis pubis*).



Pelvic joint

On the dorsal side, the pelvic bones connect to the sacrum via the sacroiliac joint (SI joint), ventrally we find a connection via the symphysis, which connects the two pelvic bones in the area of the *facies symphysis ossis pubis*.

Sacroiliac Joint

The *Articulatio sacroiliaca* connects the *os coxae* to the axial skeleton. This is a **stiff joint** (*amphiarthrosis*). The connection is ensured by strong ligaments. In the case of a woman at the end of pregnancy, their penetration occurs, which allows greater extensibility of the pelvis.

Symphysis pubica

Symphondrosis connecting the front part of the pelvic bones. The disc interpubicus, formed by a layer of fibrocartilage, is inserted between the joint surfaces. The posterior edge of the disc extends beyond the edge of the bones and arches as the *eminentia retropubica* (palpable *per vaginam* in women). Under normal circumstances, the connection is immobile. Hormonal (Relaxin) regulation at the end of pregnancy loosens the structure of the symphysis, allowing for **expansion of the pelvis during childbirth**.

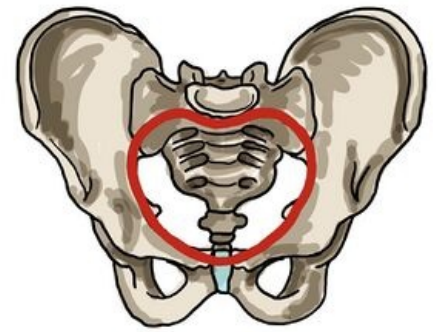
Pelvic Dissection

The pelvis is divided by the linea terminalis into a large (pelvis major) and a small pelvis (pelvis minor). It runs laterally from the promontory through the sacrum, then as the *linea arcuata* on the pelvic bone, to the *eminentia iliopubica* on the upper edge of the symphysis.

The pelvic region forms the **abdominal floor**. The small pelvis encloses the cylindrical space of the *pelvic cavity*. Cranially, it connects to the abdominal cavity in the area of the *apertura pelvis superior*, it opens caudally to the surface of the body as the *apertura pelvis inferior*.

Pelvic Planes

In order to evaluate the patency of the birth canal, the so-called **pelvic planes** were introduced, the size of which must correspond to the size of the newborn's skull in order to enable birth via the classical route. We distinguish four planes (craniocaudally): *aditus* (entrance), *amplitudo* (width), *angustio* (narrow), *exitus* (exit).



The course of the linea terminalis

Aditus pelvis

Aditus pelvis (entrance)

The plane of the pelvic entrance (*apertura pelvis superior*), copies the course of the *linea terminalis*. In the **direct** direction, we determine the *diameter recta* (connector of the promontory and the upper edge of the symphysis), **11 cm**, it is not possible to measure in clinical practice. Instead, we determine the *diameter obstetrica* (10.5 cm), *per vaginam* we measure the value of the *conjugata diagonalis* (the lower edge of the symphysis and the front edge of the promontory, approx. 12.5-13 cm) from which we subtract 2.5 cm. **Transversally** we determine the *diameter transversa* (the largest distance of the *lineae terminales*), **13 cm** and in the **oblique** direction the *diameter obliqua* (connector of SI joint and eminence iliopubica), **12.5 cm**.

During an internal gynecological examination, we evaluate the approximate value of *diameter recta aditus pelvis* by measuring *conjugata diagonalis* (from the promontory to the symphysis, by subtracting 2 cm of soft tissues, we get the approximate value of the straight diameter).

Amplitudo pelvis (width)

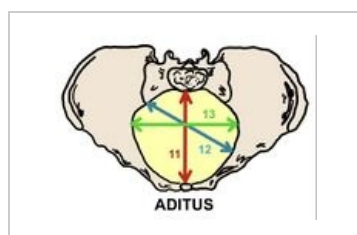
Connects the S2-S3 interface with the center of both acetabulum and the center of the symphysis. *Diameter recta* (12 cm), **diameter transversa (12 cm)** and *diameter obliqua* (13.5 cm).

Angustia pelvis (strait)

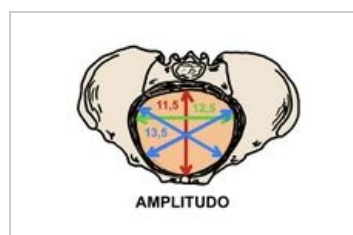
Determined as the junction of the lower edge of the symphysis, *spinae ischiadicae* and the connection of the sacrum with the coccyx. We determine two directions, *diameter recta* (joint of lower symphysis and sacrococcygeal junction), about **11.5 cm** and *diameter transversa* (between the spinae), about **10 cm**.

Exitus pelvis (exit)

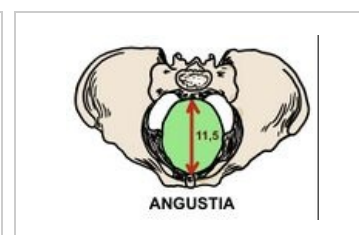
Forms *apertura pelvis inferior*. It lies in the shape of a diamond between the end of the coccyx, the *tubera ischiadica* and the lower part of the symphysis. Here we determine the important dimension *diameter recta* (9.5 cm), during childbirth the coccyx is pushed away, thereby increasing the straight dimension (11-11.5 cm), and will allow the passage of the fetus through the birth canal.



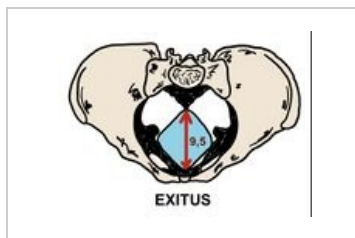
Pelvic inlet



Pelvic width



Pelvic isthmus



Pelvic outlet

Pelvic tilt

We determine standing. Basic parameters of pelvic inclination: ***inclinatio pelvis superior*** (*conjugata anatomica* makes an angle of **60°** with the horizontal), ***inclinatio pelvis inferior*** (the joint between the tip of the coccyx and the lower edge of the symphysis forms an angle of **10°**) and the angle formed by the *pelvic plane* with the horizontal (**30°**).

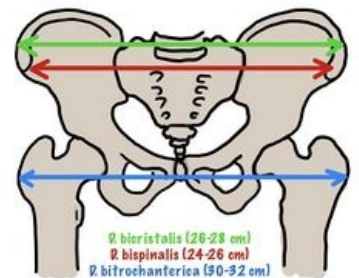
The tilt of the pelvis affects the position of the abdominal organs while standing and walking, which does not exert their full weight on the pelvic floor. During pregnancy, the growing uterus pushes the abdominal organs towards the spine, which is thus more loaded. Subsequently, compensatory hyperlordosis occurs in the lumbar region.

Measuring pelvic dimensions

External pelvic dimensions

In the prenatal clinic, we measure the pelvis from the outside using a pelvimeter (according to Baudelocque–Breisky). We measure in the position on the back, side and on the gynecological table.

- ***Distantia bispinalis*** - distance of *spinae ilacae ant. vulture*. (**25–26 cm**).
- ***Distantia bicristalis*** - the greatest distance between the ridges of the hip blades (**28–29 cm**).
- ***Distantia bitrochanterica*** - the distance between the two major trochanters (**31–32 cm**).
- ***Conjugata externa*** (*diameter Baudelocque*) - the distance between the top of Michaelis root (thorn L5) and the upper edge of the symphysis (**19–20 cm**).



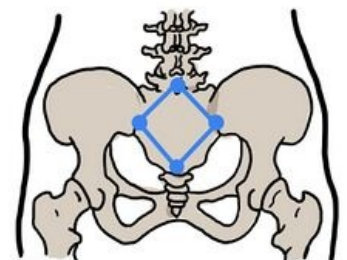
External pelvimetric examination

Internal pelvic dimensions

The approximate value of the **direct diameter of the pelvic entrance** is obtained by subtracting 9 cm from the measured value of the *conjugata externa*. Another measurable value is ***diameter transversa exitus pelvis*** (the distance of the ischial tubera). We perform the measurement on the gynecological table, using a crossed pelvimeter. Add 1.5 cm (soft tissue) to the measured value. The usual value is around **11 cm**. The distance can also be estimated using Rubešek's touch (the fist of the right hand is pressed between the tubercle, if it does not fit, it indicates a transverse narrowing of the pelvis).

The length of the ***conjugata diagonalis*** can be determined by internal examination. We introduce the pinched 2nd and 3rd fingers into the sheath, with the third finger we try to reach the promontory, while the radial edge of the hand rests on the symphysis (we mark the place of contact on the finger and then measure). The normal distance is **13 cm**. Values around 12 cm mean a borderline narrowing of the pelvis, which can be linked to complications during childbirth, values around 11 cm mean a significant narrowing of the pelvis, which can make a natural birth impossible, usually indicated for caesarean section.===Pelvic tilt measurement===

In clinical practice, we evaluate the pelvic inclination by determining the **Michaelis route** on the dorsal side of the pelvis. It is a rhombus formed by the union of the structures of the *spinae iliaca posteriores superiores*, the sacrococcygeal junction and the spine of the L5 vertebra. In a standing woman, this structure is usually visible as skin pits above the individual structures. The **longitudinal axis** of the route measures about 11 cm, the **transverse** (about 10 cm). The course of the transverse axis intersects the longitudinal axis and divides it into a cranial (4 cm) and a caudal (7 cm) section. The link between the L5 mandrel and the spins should be about 6.5 cm.

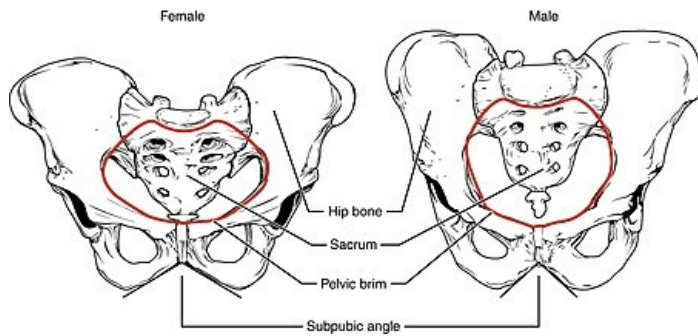


Michaelis route (dorsal)

A symmetrical Michaelis root indicates the correct shape of the pelvis. Deviations in the shape of the root are a **risk factor for cephalopelvic disproportion**. If asymmetry is detected, the birth is considered risky and a caesarean section is often indicated.

Pelvic gender differences

Gender differences in the shape of the bony pelvis are very pronounced. The shape of the female pelvis is hormonally modified during puberty and represents a significant secondary sexual characteristic. Adjusting the shape of the female pelvis is necessary for the creation of **birth canals**, which must correspond to the physiological dimensions of the newborn skull.



Female and Male Pelvic Girdle

Overall, the female pelvis is wider (more spacious) and lower than the male pelvis. The **lower arm of the pubic bones** in women converge at an obtuse angle (*arcus pubicus*) while in men they converge at a sharper angle (*angulus pubicus*). In women, the **lower arm of the pubic bone** is usually slender and smoothly curved, in the male pelvis we observe a sudden curvature in the place of the *crista phallica*.

The **Promontorium** protrudes less in the female so that the entrance to the pelvis is transversely oval, in the male it protrudes and forms a heart-shaped pelvis. ***Incisura ischiadica major*** on the female pelvis is formed by a regular arch, wider and shallowly cut, on the male pelvis the upper edge of the incision is clearly deeper. **The distance from the center of the fossa acetabuli** to the upper edge of the facies symphysis and the lower edge of the tuber ischiadicum are roughly the same in men, while in women the distance to the tuber ischiadicum is *significantly smaller than the facies symphysialis*.

The **symphysis pubica** of the female pelvis is lower (4.5 cm) than that of the male pelvis (5 cm), at the end of pregnancy it loosens and allows for a slight expansion of the birth canal. The **coccyx** is shorter and more mobile in women, it bends backwards during the passage of the fetus and thus increases the space of the birth canal (about 2.5 cm).

Types of female pelvis gynaecoid (40%), android (20%), anthropoid (25%), and platypelloid (5%) as per **Caldwell Molley classification of female pelvis** helps to assess cephalopelvic disproportion in slow progress of labour to choose the safe mode of delivery as individualised intrapartum care.

Topographical anatomy of male pelvis

Muscles of the Male Pelvic Floor

The male **pelvic floor muscles** are dome-shaped structure functions as hammock. It has three layers: deep, middle, and superficial arranged in a complex relationship with the surrounding bony pelvis, ligaments, fascia and nerves.

The muscles of the **superficial layer** are **bulbospongiosus, ischiocavernosus, superficial transverse perineal** and external anal sphincter. Their clinical significance is their involvement in ejaculation, urinary and faecal continence. The middle layer consists of **perineal membrane, the deep transverse perineal, the sphincter urethrae** and the compressor urethrae which are accountable for urinary continence during increased intra-abdominal pressure like jumping/coughing/sneezing/climbing.

The muscles of the **deep layer** are **the levator ani, iliococcygeus, ischiococcygeus** and **pubourethralis**. These act as pelvic diaphragm for pelvic organs' support towards continence. The levator ani is formed by **puborectalis, pubococcygeus, and iliococcygeus**. Around the rectum the puborectalis forms a U-shaped sling and aids in faecal continence.

The **pudendal nerve** arises from S2-4 of sacral plexus with three main branches such as the inferior rectal nerve, perineal nerve and the dorsal nerve of the penis innervating the penis, the bulbospongiosus and ischiocavernosus muscles, perineum, anus, external anal sphincter, and urethral sphincter. The sensory role of pudendal nerve are external genital sensation, bowel and bladder continence, orgasm and ejaculation.

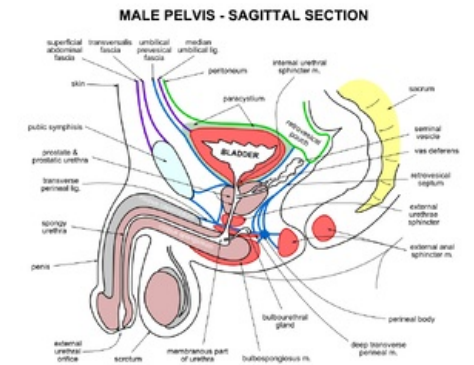
Links

Related Articles

- Foramen ischiadicum majus
- Foramen ischiadicum minus
- Pelvic floor muscles

References

- BENEŠ, George. *Study Materials* [online]. ©2009. [cit. 2010]. <<http://jirben.wz.cz>>.
- ŠIHÁK, Radomír – GRIM, Miloš. *Anatomy*. 2nd, edit. and add edition. Prague : Grada Publishing, 2002. 470 pp. vol. 2. ISBN 80-7169-970-5.
- HÁJEK, Zdeněk – CZECH, Eugene – MARSHAL, Karel. *Obstetrics*. 3. edition. Prague : Grada, 2014. 538 pp. ISBN 978-80-247-4529-9.



male pelvis sagittal section