

# Posterior spinal cord syndrome

**The syndrome of the posterior spinal cords** manifests itself mainly in a disorder of tactile and vibrational sensation. The disabled also suffer from ataxia, which manifests itself when the eyes are closed. The perception of pain, temperature and soft touch is not affected. Typical is a way of walking that is rough and the patients have a hard time stepping. Subjectively, however, they compare contact with the mat to walking on moss.

## Posterior spinal cord

- *Fasciculus gracilis*
- *Fasciculus cuneatus*

The posterior cords are formed by long axons of neurons, the body of which is stored in the spinal ganglia. It is an **ascending** three-neuron pathway that carries information about depth sensation, vibration, and proprioception. It is sometimes also called the lemniscal system. The nucleus gracilis and nucleus cuneatus are located in the medulla oblongata, in which the neurons connect and lead as a lemniscus medialis (crossing occurs at the level of the oblongata) to the area of the thalamus. In the thalamus, the three-neuron path connects for the last time in the nucleus ventralis posterolateralis (NVPL), and the fibers end in the cerebral cortex - in the postcentral gyrus.

## Causes

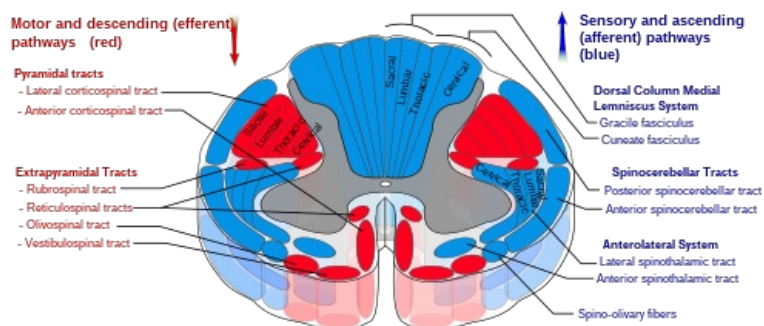
- Trauma
- spinocerebellar ataxia
- tabes dorsalis
- pernicious anemia

## Links

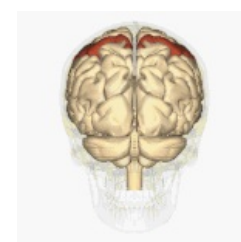- Traumatic spinal cord syndromes
- Spinal medulla
- Spinal tracts
- Pernicious anemia
- Ataxia

## References

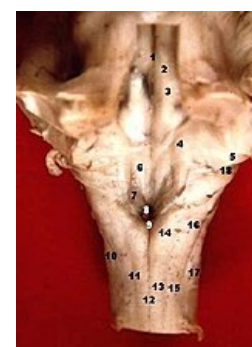
- AMBLER, Zdeněk – BEDNAŘÍK, Josef. *Klinická neurologie : část speciální. II.* 1. edition. Triton, 2010. ISBN 978-80-7387-389-9.
- – GRIM, Miloš. *Anatomie 3. 2., upr. a dopl. edition.* Grada, 2004. 673 pp. ISBN 80-247-1132-X.
- DRUGA, Rastislav – GRIM, Miloš – DUBOVÝ, Petr. *Anatomie centrálního nervového systému.* 1. edition. Galén; Karolinum, 2011. 219 pp. ISBN 978-80-7262-706-6.



Tracts of the spinal cord.



Postcentral gyrus



13. fasciculus gracilis  
15. fasciculus cuneatus