

Hemangioma

Hemangioma is a neoplasm that occurs in the skin as well as organs. It has its own vascular structure. It is a benign flat formation arching above the surface of the mucosa. It has a red to reddish-brown color. The size is usually a few mm to a few cm. When pressed with a finger, the hemangioma temporarily pales.

Occurrence

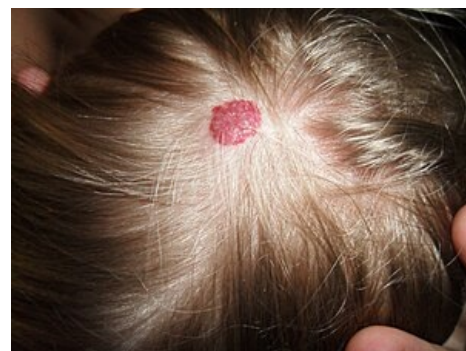Congenital forms appear at birth or in early childhood, they do not have a tumor character, they are developmental defects.

Senile angioma occurs in the elderly, and vascular ectasia develops on the lips.

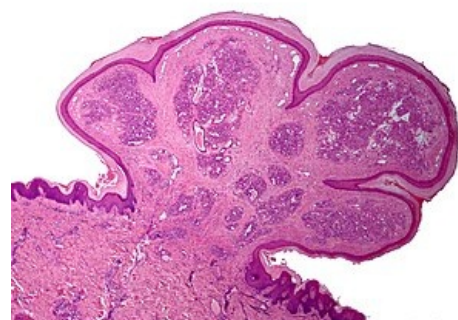
The most common localization is the lip, tongue, facial mucosa or palate.

Hemangiomas in children

Hemangiomas can develop at any time during the first months of life. They are present in 10% of children at one year of age. Children's hemangiomas tend to disappear - 50% disappear within 5 years of age, 90% within 10 years of age. Atrophy, telangiectasia, hypopigmentation or scar may subsequently develop at the site of the hemangioma. Multiple skin hemangiomas may be accompanied by hemangiomas of the liver and gastrointestinal tract with a risk of obstruction or bleeding. Rarely, large and multiple hemangiomas lead to heart failure due to high cardiac output.^[1]



Hemangioma on the hairy part of the head.



Granuloma pyogenicum

Granuloma pyogenicum

Granuloma pyogenicum is a benign mesenchymal tumor, consisting mainly of granulation tissue. It is also called a lobular capillary hemangioma. It grows quickly and tends to be red. It is usually exulcerated. It is formed in soft tissues after minor trauma and intrusion of the microorganism. It is being treated surgically. It is the source of epistaxis. We find it in the vault of the nasopharynx. Malignant variants, angiosarcomas, are rare.

Resources

Related articles

- Liver hemangioma (preparation)
- Blood vessel tumors

References

1. MCLAUGHLIN, M R, et al. *Newborn Skin: Part II. Birthmarks* [online]. American Family Physician, ©2008. [cit. 2012-09-04]. <<https://www.aafp.org/afp/2008/0101/p56.html>>.

Literature

- LIŠKA, Karel. *Orofaciální patologie*. 1. edition. Praha : Avicenum, 1983. 159 pp.

External links

- Hemangiom (Czech wikipedia)
- Hemangioma (English wikipedia)