

# Salivary Glands

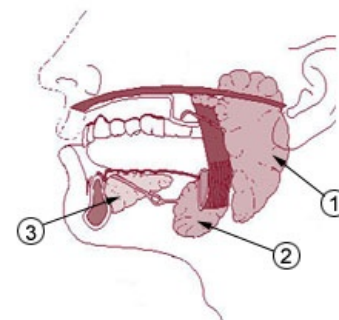
The salivary glands consist of: Parotid, Sublingual and Submandibular glands.

## Parotid Gland

- It is the largest of all three glands
- It is located on the anterior, lower half of the ear
- It has an excretory duct.
- Parasympathetic innervation is by glossopharyngeal nerve

## Sublingual and Submandibular Gland

- They are mixed seromucous glands
- They have an excretory duct
- Parasympathetic innervation is by chorda tympani (from the superior salivatory nucleus) and a branch of the facial nerve (which synapses with the submandibular ganglion, follows the lingual nerve and leaves the lingual nerve when it is near to the glands<sup>[1]</sup>)



1. Parotid gland 2. Submandibular gland  
3. Sublingual gland

## Sublingual Gland

- It is the smallest salivary gland
- It is almond-shaped
- It is lateral to the submandibular duct
- It is associated with the lingual nerve on the floor of the oral cavity
- The gland lies against the medial surface of the mandible, where it forms the sublingual fossa, lying superior to the anterior 1/3 of the mylohyoid gland

## Submandibular gland

- It is on the medial side of the mandible in the submandibular fossa, which is inferior to the mylohyoid line
- The larger arm of the hook is directed forward in the horizontal plane; below the mylohyoid muscle
- The smaller arm loops around the posterior margin of the mylohyoid muscle

## Links

## Bibliography

SNELL, Richard S. *Clinical Anatomy by Regions*. 8th Edition edition. 2004. ISBN 978-0-7817-6404-9.

## References

1. Wikipedia. *Submandibular gland* [online]. The last revision 2011-11-11, [cit. 2012-02-29]. <[http://en.wikipedia.org/wiki/Submandibular\\_gland#Innervation](http://en.wikipedia.org/wiki/Submandibular_gland#Innervation)>.