

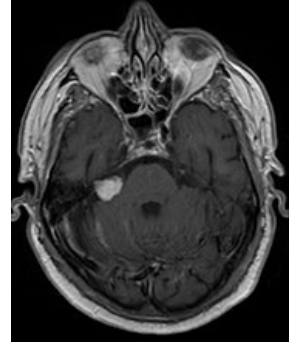
# Tumors of peripheral nerves

**Peripheral nerve tumors** can arise from **Schwann cells, fibroblasts** or **perineural cells**.

Among the most important representatives are "neurinoma (*schwannoma, neurilema*)", *neurofibroma, tumor of granular cells*, as well as perineurioma, neurothecoma or malignant peripheral nerve sheath tumor (MPNST - malignant peripheral nerve sheath tumor).

## Schwannoma

- Occurs either sporadically or as part of **neurofibromatosis type II**.
  - In neurofibromatosis, these are usually multiple, chain-like tumors of various sizes on many nerves.
- The tumor usually destroys the fascicle from which it originates, the other fascicles follow the tumor and are stretched and compressed.
- They are also of considerable size.
- **Therapy:** the tumor has a capsule, the functional fascicles are usually easily separated from the capsule and only the tumor is removed.
  - Paresis may improve over time.
- In the histological image, two variants of the tumor are visible, referred to as *Antoni variant A and B*. Type A is characterized by its staggered nuclei, such an arrangement is referred to as Verocay bodies. Type B shows a more myxoid character, it does not contain stapling of the nuclei. Both variants can be found in the same tumor.



Schwannoma on MRI

## Links

### Related Articles

- Cubital tunnel syndrome
- Carpal tunnel syndrome
- Meralgia paraesthetica

### Source

- BENEŠ, Jiří. *Studijní materiály* [online]. ©2007. [cit. 2010]. <<http://www.jirben.wz.cz/>>.

### References

- ZEMAN, Miroslav, et al. *Speciální chirurgie*. 2. vydání. Praha : Galén, 2004. 575 s. ISBN 80-7262-260-9.
- POVÝŠIL, Ctibor, et al. *Obecná patologie*. 1. vydání. Praha : Galén, 2011. 290 s. ISBN 978-80-7262-773-8.

Retrieved from "[https://www.wikilectures.eu/index.php?title=Tumors\\_of\\_peripheral\\_nerves&oldid=77304](https://www.wikilectures.eu/index.php?title=Tumors_of_peripheral_nerves&oldid=77304)"