

Cerebral cortex

Cerebral cortex (cortex cerebri) is a term denoting the surface of the terminal brain (telencephala), which covers the white matter of the cerebral hemispheres. The CNS neuron bodies are mainly stored here. Leptomeninges, pachymeninx, calva and dermis attach to the cortex towards the surface of the body. The cortex contains 3-6 layers of neurons, the number of which depends on the developmental age of the specific cortical area.

Developmental breakdown

In terms of development, the cerebral cortex can be divided into **paleocortex, archicortex and neocortex**.

Allocortex is a designation for developmentally older structures, i.e. paleocortex and archicortex. Characteristic of these areas is that, unlike the neocortex, only 3 cell layers can be distinguished.

Paleocortex

The **paleocortex** is phylogenetically the oldest part of the cortex, it is located in the functional cortical area for smell - it forms the **rhinencephalon**. Overall, it has three layers of neurons, occupying approximately 1% of the total cortical surface area.

Archicortex

The archicortex takes up approximately 4% of the cortical surface. It is located in the depth of the temporal lobe and on its lower edge, where it migrated during development from its original location on the medial surface of the hemisphere. It is functionally involved in the limbic system and at the same time has very close both anatomical and synaptic communication with the paleocortex.

Neocortex

The neocortex (also isocortex) is the youngest in development, but at the same time takes up to 95% of the total surface of the cortex and is the seat of the highest nervous functions. Neocortical neurons are arranged in 6 layers.

1. **The lamina molecularis** forms the surface of the cortex, it contains fewer neurons compared to the other layers. It is made up mainly of glial cells, interneurons and nerve fibers. Through the membrana limitans gliae superficialis, the layer is in contact with the pia mater.
2. **The lamina granularis externa** consists primarily of stellate cells, which together create mainly associational communication.
3. **The lamina pyramidalis externa** contains interneurons together with small pyramidal cells, together they form commissural pathways.
4. **The lamina granularis interna** is primarily made up of stellate cells, its predominance is in the sensitive and sensory area. Also most of the fibers entering the cortex end here.
5. **The lamina pyramidalis interna** contains large pyramidal cells, at the same time it prevails in the motor area - it is a source of efferent to other parts of the CNS.
6. **Lamina multiformis** occurs in the depth of the cortex, it is formed by association interneurons.

In addition to the mentioned cells, there are also other types of neurons in the neocortex. These are, for example, horizontal Cajal cells (neura horizontalia), basket-shaped cells (neura corbiformia), gliaform cells (neura neurogliaformia), etc.

Heterotypic and homotypic cortex

Heterotypic neocortex takes up all association areas of the cerebral cortex, characterized by less histological differentiation of individual layers.

The homotypic cortex is further divided into the granular homotypic neocortex (more granular cells are represented here, typical localization is in the primary somatosensitive visual and auditory areas) and the agranular homotypic neocortex (more pyramidal cells, localization in the primary motor cortex - gyrus praecentralis).

The cortex also has its own myeloarchitectonics, i.e. the arrangement of nerve fibers. We can distinguish radial stripes (radia) and horizontal or tangential stripes (striae with the following nomenclature):

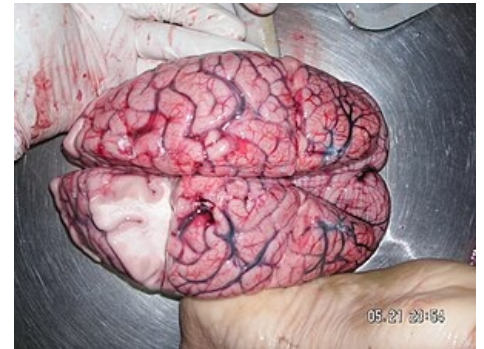
1. layer - **Exner strip**,
2. layer - **Bechtěrev's strip**,
3. layer - **outer Baillarger strip**,
4. layer - **inner Baillarger strip**,
5. layer - **Meynert strip**.

Brodmann's areas

Brodmann's areas are a system used to divide the cerebral cortex on the basis of cytoarchitectonic organization, which is why we can meet the term **cytoarchitectonic map**. This classification is based on the fact that the human cerebral cortex consists of a total of **six cell layers**, the density and overall architecture of which varies from region to region. Brodmann divides the cortex into **52 regions** (numbered sequentially). Various areas are also assigned a function based on their physiological properties, which is why they are called **functional cortical areas**. It should be noted that the motor areas have mainly the 3rd and 5th layers developed, while the areas for sensitive stimuli are more likely the 2nd and 4th layers.

Functional breakdown

Functional area	Exact areas	Brodmann's areas
Motor area	<ul style="list-style-type: none"> ▪ Primary motor area ▪ Secondary motor area ▪ Premotor and supplementary motor area ▪ Frontal oculomotor field 	<ul style="list-style-type: none"> ▪ BA 4 ▪ BA 6 ▪ BA 8
Somatosensitive area	<ul style="list-style-type: none"> ▪ Primary somatosensitive area ▪ Association somatosensitive cortex 	<ul style="list-style-type: none"> ▪ BA 1, 2, 3 ▪ BA 5, 7
Sensory area	<ul style="list-style-type: none"> ▪ Primary visual area ▪ Secondary visual area ▪ Primary auditory region ▪ Secondary auditory region ▪ Taste area ▪ Olfactory area ▪ Vestibular area 	<ul style="list-style-type: none"> ▪ BA 17 ▪ BA 18, 19 ▪ BA 41, 42 ▪ BA 22 ▪ BA 43 ▪ BA 28 ▪ BA 2
Speech area	<ul style="list-style-type: none"> ▪ Broca's motor speech center ▪ Wernicke's sensory speech center 	<ul style="list-style-type: none"> ▪ BA 44, 45 ▪ BA 22, 39, 40
Association area	<ul style="list-style-type: none"> ▪ Frontal association area ▪ Parietal association area ▪ Temporal association area ▪ Occipital association area 	<ul style="list-style-type: none"> ▪ BA 9-12, 46, 47 ▪ BA 5, 7, 39, 40 ▪ BA 20-22, 37, 38 ▪ BA 18, 19
Limbic area	<ul style="list-style-type: none"> ▪ Limbic area (part of the limbic system) 	<ul style="list-style-type: none"> ▪ BA 23-36
Multifunctional area	<ul style="list-style-type: none"> ▪ Insular region 	<ul style="list-style-type: none"> ▪ BA 13-16



Human brain taken from autopsy.

Cortical areas for motor skills

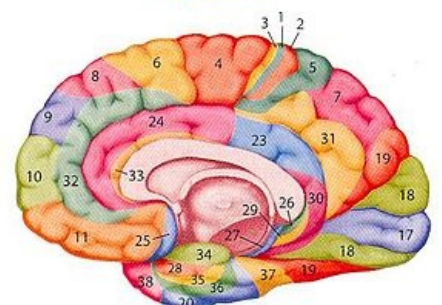
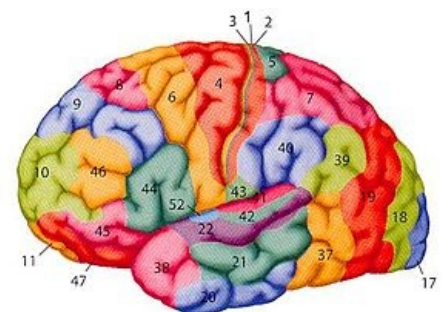
Primary motor area (M1)

The primary motor area is located in the **gyrus praecentralis**; i.e. **Brodmann's area 4** - its function is to ensure free motor skills. The afferent goes from the premotor area, the primary somatosensitive area and from the nucleus ventralis lateralis thalami. From this region, the corticospinal tract ascends into the spinal cord and towards the cranial nerve nuclei.

The motor cortex is organized **somatotopically**, when certain parts of the body have a larger projection than would correspond to their size ("they are better innervated") - the designation **motor homunculus**. The upper part of M1 controls the muscles of the leg, lower limb, trunk and upper limb, the remaining parts towards the sulcus lateralis control the muscles of the hand, neck, face, larynx and tongue. Bidirectionally, M1 is also connected to the main sensitive area of the cortex.

The stimulus causes muscle contraction on the contralateral half of the body, so the damage leads to **spastic paralysis**.

Secondary motor area (M2)



Unlike M1, the secondary motor area is located in the **superior frontal gyrus; Brodmann's area 6** - is important for more **complex** movements of the head, limbs and the initiation of movements.

In the event of a disorder in this area, **spastic paralysis** and **speech stoppage** occur.

Premotor a supplementary area

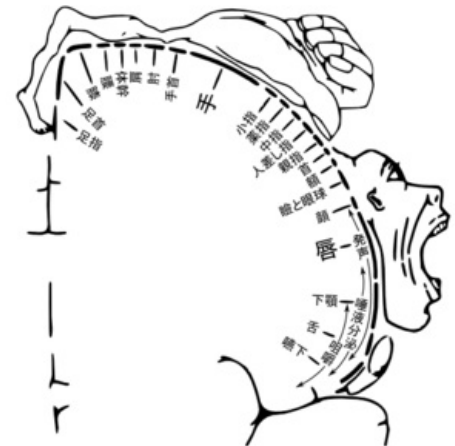The premotor area is connected to M2, it is located in the **posterior part of the superior frontalis gyrus** and in the **anterior part of the precentralis gyrus; Brodmann's area 6** – purposefully prepares and changes movements, cooperates with the frontal oculomotor field (FEF) (see below) during visual inspection of the surroundings. Fibers arriving in this area originate from the nucleus ventralis anterior thalami and association areas. Conversely, efferent fibers lead to the primary motor area, cerebellum, basal ganglia, reticular formation and nucleus ruber.

The damage leads to **ideomotor apraxia** - the patient is unable to imitate certain movements, e.g. unlocking the door.

Frontal eye field (FEF)

The frontal oculomotor field is located in the **gyrus frontalis** (adjacent to the premotor area); **Brodmann's area 8** – afferent fibers come from the primary and secondary visual areas and nucleus dorsomedialis thalami. The FEF participates in conjugate eye movements, and is also involved in the oculomotor circuit of the basal ganglia.

The malfunction is **bulb deviation**.



motor homunculus in Japanese language

Areas for somatosensitive sensations

Primary somatosensory area (S1)

The primary sensitive area is located in the **gyrus postcentralis** and the **posterior part of the lobulus paracentralis; Brodmann's areas 1, 2, 3**. Sensitive pathways from the body via the nucleus ventralis posteromedialis thalami and from the head via the nucleus ventralis posterolateralis thalami and association nuclei of the thalamus come to this place. In areas adjacent to the sulcus centralis, primarily somatosensitive fibers with information from surface skin receptors are projected, and proprioceptive information originating from tendons and joints is projected to the posterior parts.

As in the case of the primary motor area, the **somatotopic organization** of the cortex - **the sensitive homunculus** - is also present in the primary sensitive area. The so-called "hanging by the leg" homunculus - the lower limb projects into the medial part of the gyrus precentralis/gyrus postcentralis supplied from the anterior cerebral artery, the rest of the body projects laterally into the area supplied by the medial cerebral artery. This is of practical importance in cerebrovascular accident ("stroke").

Stimuli cause sensations of touch on the contralateral half of the body, the disorder is **hypoesthesia**. In the basin of the a. cerebri anterior, only the distal part of the lower limb is affected, during stroke in the basin of the a. cerebri media, a typical **hemiplegia** appears, possibly loss of sensitivity of the upper limb, trunk and proximal part of the lower limb with preservation of the function of its distal part.

Secondary somatosensitive area (S2)

The secondary sensitive area represents the upper part of the lateral fissure in the **postcentral gyrus** (lobus parietalis); **Brodmann's area 40**, above the sulcus lateralis along the operculum – stimulation leads to a feeling of less precise sensation, especially on skin stimulation. Compared to S1, it is less significant. Afferent leads from the primary somatosensitive area and the thalamus.

Association somatosensitive cortex

The association somatosensitive cortex is located in the area of the **lobuli parietales; Brodmann's areas 5, 7** – have the task of analyzing and integrating the somatosensitive afferent of touch, position (proprioception), perceiving movement and orientation in space, and thus creates a spatial idea and the mutual relations of individual body parts. Afferent leads from the sensitive and association areas of the cortex and thalamus from the nuclei posteriores and nuclei intralaminares thalami.

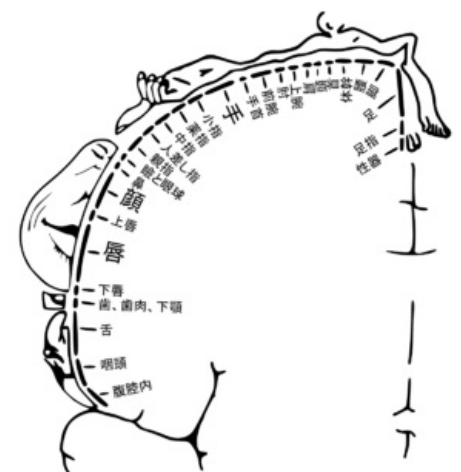


diagram showing position of regions of the human cortex corresponding to the respective afferent nerve region of the body. Writing in Japanese language

Areas for sensory perception

Primary visual area (V1)

The primary visual area (V1 – from English visual) is located in the area of the **sulcus calcarinus; Brodmann areae 17**, the medial surface of the occipital lobe – ensures the perception of seen objects. Afferent leads from nucleus corporis geniculati lateralis thalami via radiatio optica. From this area, further efferent leads to the secondary visual area.

Damage results in **cortical blindness**.

Secondary visual area (V2)

The secondary visual area is located in close proximity to the **primary visual area; Brodmann areae 18, 19** - its function is a more detailed **analysis of what is seen**, visual memory is located here. Outside this region, fibers from the primary visual area lead. From V2, fibers continue to the area pretectalis, the premotor area and the frontal oculomotor field.

In the case of its damage, **visual agnosia** is present - the patient sees and is aware of it, but is unable to name the objects seen.

Primary auditory area (A1)

The primary auditory area A1 occurs in the lower part of the fissura cerebri lateralis, in the **gyri temporaes transversi** (Heschl's convolutions) on the upper surface of the gyrus temporalis superior; **Brodmann's areas 41, 42** - its task is to ensure the awareness of individual tones and sounds. Afferent fibers lead to A1 from nucleus corporis geniculati medialis thalami via radiatio acustica, efferently to speech and association areas.

The disorder is **deafness**, so there is a bilateral hearing impairment. In the case of damage to the front part, patients are unable to hear low-frequency sounds, while damage to the back part affects high frequencies.

Secondary auditory area (A2)

The secondary auditory area is located in the **superior temporal gyrus; Brodmann's area 22** - its function is the analysis, recognition and more complex perception of sounds and voices. Outside this region, fibers from the primary auditory region and from the nucleus corporis geniculati medialis thalami lead. Efferent fibers lead to speech and association areas.

In the event of a disorder in this area, the patient is unable to **interpret individual sounds and voices**.

Taste area

The taste cortical area is located in the **postcentral gyrus** (pars opercularis) and in the adjacent cortex of the lobus insularis; **Brodmann's area 43** – is responsible for the processing of taste sensations (taste pathway). Fibers outside this area run from the nuclei tractus solitarii through the nucleus ventralis posteromedialis thalami.

Olfactory area

The olfactory cortical area is located outside the **gyrus parahippocampalis**, i.e. the area entorhinalis; **Brodmann's area 28** – processing of olfactory sensations (olfactory pathway), corresponds to the **paleocortex**. Afferent fibers lead from the bulbus olfactorius, through the tractus olfactorius, and the stria olfactoria lateralis. At the same time, the olfactory area is connected to the orbitofrontal association area.

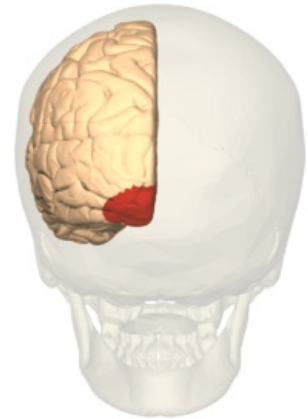
Vestibular area

This area occurs in a relatively small section in the **gyrus postcentralis**, very close to the sulcus lateralis; **Brodmann's area 2V** - awareness of the movement of the head in space occurs thanks to it. Fibers leading to the vestibular cortical region come from the nuclei ventrales posteriores.

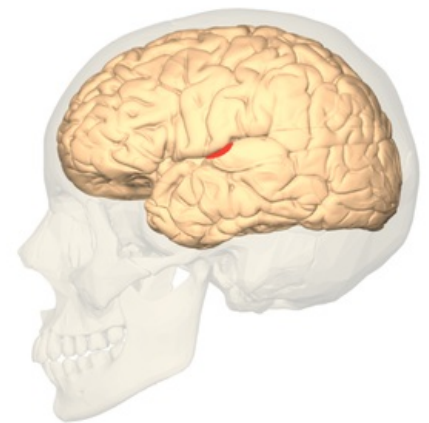
Speech centers

Broca's speech motor center

Broca's speech center is located in the area of the **inferior frontalis gyrus, pars triangularis; Brodmann's areas 44, 45** - primarily involved in the formation of words, sentences and written speech, in right-handed and most left-handed people it is located on the left. For normal function, proper function of the PM, M1, M2 areas is also required. The connection of Broca's and Wernicke's centers (through the fasciculus arcuatus) together with association areas is fundamental.



Brodmann area 17 (shown in red).



Primary auditory cortex (PAC)

The impairment is **expressive Broca's aphasia** — it causes speech impairment, comprehension is fine. If the brain involvement due to stroke involves Broca's area, the surrounding motor cortex is usually also affected and the patient has hemiplegia at the same time. Since the majority of the population has the left hemisphere as a speaker, its impairment is associated with right-sided hemiplegia (crossing of the corticospinal tract in the region of the medulla oblongata).

Wernicke's sensory speech center

Wernicke's center is usually in the left hemisphere (always the **dominant** one) in the **superior temporal gyrus** and in the adjacent parietal cortex, i.e. the inferior lobulus parietalis; **Brodmann's areas 22, 39, 40** - primarily responsible for understanding the heard word and written text. Afferent leads from auditory and visual cortical areas.

The damage leads to **perceptual aphasia** - it means that the patient hears, but does not understand the meaning of individual words and the formulation of sentences. The person can speak, but his speech is incomprehensible. The center is further away from the motor cortex, the patient is more often without hemiplegia.

Association cortical areas

These areas make up up to 75% of the cerebral cortex. Some areas of the cortex are not typical for the performance of a single function, but in them the integration of somatosensitive, auditory and visual sensations occurs. They are located in the prefrontal, parietal, temporal and occipital regions. The cortex of the frontal lobe is connected to the reticular formation, the thalamus and the limbic system. Basically, we can divide individual association areas into 4 categories according to their location:

- **parietal association areas** – are located in the lobulus parietalis superior/inferior (gyrus supramarginalis, gyrus angularis), participate in the complex perception of objects, create spatial maps of the surroundings;
- **temporal association lobes** – are located in the temporal lobe and occipitotemporal gyrus, their primary function is to recognize faces and types of objects;
- **occipital association areas** – are found in the lobus occipitalis, their goal is detailed analysis and visual gnosis, i.e. recognition of what is seen;
- **prefrontal areas** - represent regions in the prefrontal cortex, which is located in the gyri frontales, gyri rectus and gyri cinguli, there is a cortical center for emotions, behavior, planning, creative thinking, etc.

Damage to this area leads to **apathy, lack of interest in one's own person, personality deprivation and emotional lability**. Severing these connections was the essence of the previously used frontal lobotomy. In its time, it was a frequently used, albeit controversial, method of treating some psychoses. In case of dysfunction of the parietal association area, there is usually an inability to name a specific object.

Multifunctional cortical areas

Multi-functional areas also project to the lobus insularis and have many functions. We can divide them as follows:

- **viscerosensitive part** - this is the ventral part whose function is the perception of taste and the involvement of this area in olfactory perception and regulation of the immune response, in cooperation with the hypothalamus it regulates the activity of the sympathetic and parasympathetic;
- **motor part** - this is the middle part, its function is primarily to influence respiratory and articulatory movements together with speech and peristalsis
- **vestibular part** - the last dorsal part, functionally involved in the perception of movements and head position.

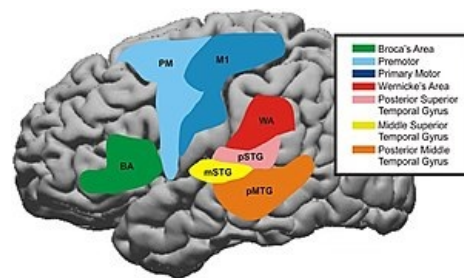
Poškození funkce inzuly se nejčastěji projevuje **změnou dechové frekvence, poruchami srdečního rytmu, k útlumu** nebo naopak **abnormálním zrychlením peristaltiky**, případně i **poruchami řeči**.

Damage to the function of the insula is most often manifested by a **change in respiratory rate, heart rhythm disorders, a decrease** or, conversely, an abnormal **acceleration of peristalsis**, or even **speech disorders**.

Links

Related articles

- Brain
- Telencephalon
- Cerebrospinal fluid
- Cerebrospinal sheaths
- Cytoarchitectonics of the cerebral cortex



The time course for cortical areas that have been shown to be involved in speech processing were summated across patients. These areas were Premotor area [PM, Brodmann's Area (BA) 6], primary motor area (M1, BA4), middle superior temporal gyrus (mSTG, middle portion of BA22), posterior superior temporal gyrus (pSTG, BA41+42), Broca's Area (BA44+45), Angular gyrus—Wernicke's area (WA, BA39+40) and also posterior middle temporal gyrus (pMTG, posterior part of BA21).

References

- NAŇKA, Ondřej a Miloslava ELIŠKOVÁ. *Přehled anatomie*. 2. vydání. Galén, 2009. 4 s. s. 295-298. ISBN 978-80-7262-612-0.
- AMBLER, Zdeněk a Josef BEDNAŘÍK, et al. *Klinická neurologie*. 2. vydání. Praha : Triton, 2008. ISBN 978-80-7387-157-4.
- HUDÁK, Radovan a David KACHLÍK. *Memorix anatomie*. - vydání. Triton, 2017. ISBN 9788075534200.