

Thrombosis

Thrombosis is defined as *intravital blood clotting in the vessels and heart*.

- **Thrombus** is *intravital* formed blood clot (macroscopically: rigid, dull surface, firmly adheres to the vessel walls).
- **Cruor** is *posthumously* formed blood clot (macroscopically: pliable, shiny surface, can be easily separated from the wall).
- **Coagulum** is the generic name for a clot, a precipitate formed outside the organism (e.g. after collection in a test tube).

Classification of thrombi

According to the size we distinguish:

1. **obturing** - completely clogs the affected blood vessel (located in the veins)
2. **mural** - occludes the vessel only partially (located in the heart and aorta).

According to the macro- and microscopic appearance, we distinguish:

1. **red** (stagnant - formed in stagnant blood) - fibers of fibrin + erythrocytes, almost always obturative, in the veins of the lower extremities;
2. **white** (flux - arises in flowing blood) - fibrin fibers + leukocytes (polymorphonuclear) + thrombocytes, especially on the edges of heart valves and in places of fast blood flow (aorta and arteries);
3. **mixed** - fibrin + erythrocytes + leukocytes - arises from a white thrombus by the deposition of erythrocytes (platelets with fibrin and leukocytes, between which there are bands of erythrocytes - *coral thrombus*; in thrombi formed in aneurysms, the layering can be concentric - **layered thrombus**);
4. **platelet** - fibrin + platelets - microscopic, is in venules and sinusoids;
5. **hyaline** - fibrin + platelets - microscopic, it is in the capillaries, mainly in the CNS, lungs and kidneys during shock, some infections, burns, etc.

Pathogenesis of thrombosis

Thrombosis occurs when the balance between hemocoagulation and fibrinolysis is disturbed (if hemocoagulation predominates, thrombosis occurs, if fibrinolysis predominates, bleeding occurs = hemorrhagic diathesis). Three basic factors apply (Virchow's Trias):

1. **slowing of blood flow** (veins of the long-term immobilized, lugs of a failing heart, aneurysms, venostasis);
2. **damage to the vascular wall** (especially to the endothelium - activation of factor XII in contact with negatively charged collagen, causing atherosclerosis, punctures, sutures, endocarditis, phlebitis + arteritis, infarct focus);
3. **change in blood composition** (increased blood viscosity - increased hematocrit).

Activation of factors by substances:

- *Exogenous* - hormonal contraceptives (estrogens), endotoxins and other bacterial products causing DIC;
- *Endogenous* - released from tumours or damaged tissues (thromboplastin, mediators of inflammation).

Consequences of thrombosis

- In **arteries** - ischemia;
- In **veins** - venostasis.

The further fate of the thrombus

1. **Organization of the thrombus** - the vessel wall under the thrombus suffers hypoxia and undergoes necrosis, which is destroyed by reparative inflammation (along the fibrin fibers penetrate blood vessels and fibroblasts, i.e. granulation tissue - the thrombus is organized by granulation tissue, resulting in thickening of the vessel wall under the thrombus).
2. **Continued thrombosis** is characterized by continued thrombus growth in the unfixed section.
3. **The detachment of a thrombus** with its subsequent ejection (embolization) into a blood vessel is called thromboembolism (from the veins of the lower limbs and from the right ostium to the pulmonary artery, from the left ostium to the brain, renal and mesenteric arteries, to the arteries of the lower limbs - ICHDK induced

either directly by thrombosis or thromboembolism), if it was the disintegration of an infected thrombus in purulent thrombophlebitis, *peripheral pyaemia* occurs, in the case of vegetations in infective endocarditis, *central pyaemia* occurs.

4. **The secondary change** is calcification of the thrombus in the veins - *phlebolith*.
5. **Puriform softening** - the central areas of the thrombus undergo lysis (induced leukocytes) and turn into a pus-like mass. (The thrombus then resembles a pouch filled with pus, but it is not true pus; in the case of purulent phlebitis with seeding thrombosis and infection of the thrombus, its purulent disintegration occurs - bacteria are present.).
6. **Thrombus hyalinization** - swelling of fibrin fibres in older mural thrombi, such fibres then form a homogeneous mass with other components of the thrombus (discolouration + solidification).
7. **Recanalization** in the obturator thrombus (capillaries of granulation tissue originating from the vessels of the adventitia form junctions between the vascular sections separated by the thrombus).

DIC (disseminated intravascular coagulation)

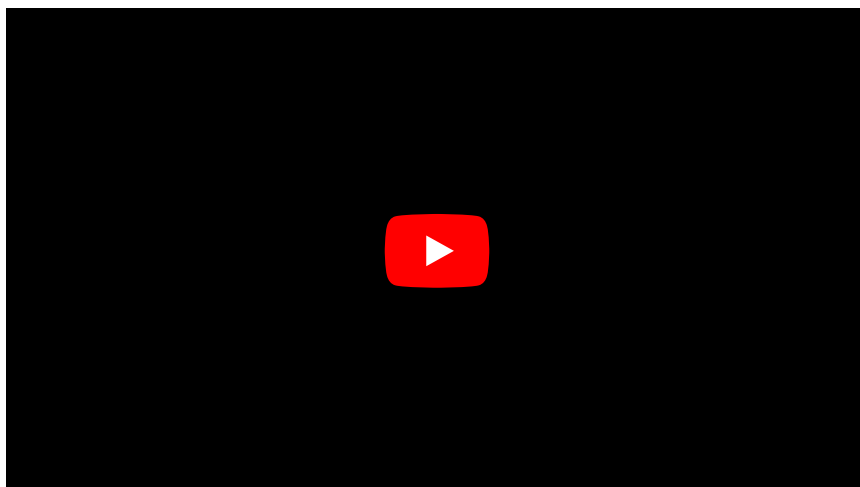
- Definition: **the initiation of a hemocoagulation cascade that, by depletion of coagulation factors, leads to increased bleeding (consumptive coagulopathy).**

Physiologically, blood clotting is only a local process at the site of injury, but in DIC, the triggering moment is such that blood clotting occurs simultaneously at different sites (even undisturbed) in the vasculature, The cause is the pathological presence of a **tissue factor** (factor III - **tissue thromboplastin**), which is a cofactor of factor VII - the binding of factor III to factor VII produces VIIa, which in the presence of calcium activates factor X and thus triggers the haemocoagulation cascade. The source of tissue factor (III - tissue thromboplastin) may be:

- **Cells from tissues other than blood** that enter the blood, e.g. during childbirth (amniotic fluid embolism), during extensive injuries, surgery or with the penetration of cancer cells into the circulation).
- **Pathological blood cells** in myelo- and lymphoproliferative diseases that may contain tissue factor in their membranes.
- **Activated endothelia and monocytes** (by endotoxin, systemic inflammation), which can begin to express tissue factor in their cell membrane.
- cytoplasmic tissue factor released from **hemolyzed erythrocytes**.

Microthrombi are formed in capillaries of mainly parenchymatous organs (liver, kidneys, lungs), but also in myocardium and brain - subsequent ischemia leads to insufficiency of affected areas up to multi-organ failure. At the same time, there is a depletion of coagulation factors and platelets (**consumption coagulopathy**) and an increase in fibrinolysis (manifested by an increase in fibrin degradation products, especially D-dimers, which can be determined by specific antibodies, fibrinogen concentrations are significantly reduced), leading to multiple bleedings (gingival and GIT bleeding, haematuria, epistaxis, haematoma formation, bleeding from surgical wounds and injections, bleeding into internal organs incl. bleeding into the brain).

The mortality rate is about 40%.



Links

Related articles

- [Plate plug](#)
- [Embolism](#)

- Platelets
- Coagulation disorders
- Hemostasis

Used literature

- PASTOR, Jan. *Langenbeck's medical web page* [online]. [cit. 2010-03-06]. <<http://langenbeck.webs.com>>.
- POVÝŠIL, Ctibor. *Local circulatory disorders* [lecture for subject Pathology, specialization general medicine, 1. medical Charles University]. Prague. 3/11/2015.