

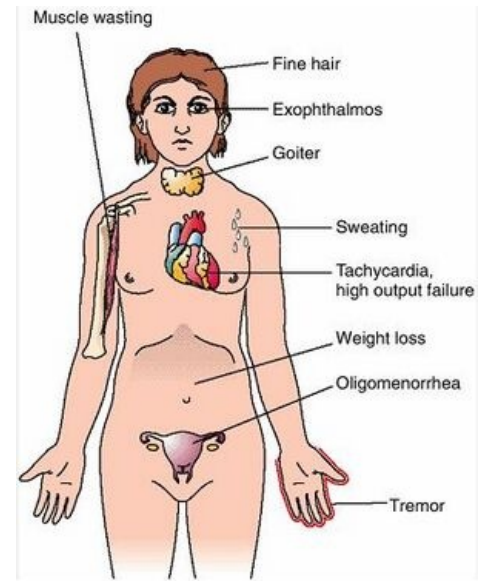
# Thyrotoxicosis

**Thyrotoxicosis** is a condition in which tissues are exposed to high levels of circulating thyroid hormones. The most common cause of thyrotoxicosis is Hyperthyroidism<sup>[1]</sup>, ie excessive thyroid function. Usually in practice, the two terms are often confused.

## Etiopathogenesis

### Hyperthyroidism

- Graves' disease - the most common cause of hyperthyroidism; antibodies against receptors for TSH (TRAK);<sup>[2]</sup>
- Hyperfunctional goiter
- **Hyperfunctional thyroid adenoma** - very rare
- **Pituitary adenoma** secreting TSH - very rare
- Increased secretion of hCG - hCG and TSH are glycoprotein hormones and are partly similar, so at higher concentrations there may be cross-reactivity with TSH receptors, eg pregnancy (mostly at the end of the 1st trimester), hCG-producing mole hydatidosis, testicular tumor



Symptoms and signs of hyperthyroidism

### Other (not included in hyperthyroidism)

- **Thyroiditis** - can cause transient thyrotoxicosis due to the disruption of thyroid follicles by inflammation and the release of stored hormones into the blood. Hypothyroidism usually occurs afterwards. Eg: Hashimoto's thyroiditis, subacute granulomatous thyroiditis, subacute lymphocytic thyroiditis
- Ovarian goiter - ovarian teratoma, producing thyroid hormones
- Thyrotoxicosis factitia - overdose of thyroid hormones or preparations with iodine (contrast agents, **amiodaron**)
- Neonatal thyrotoxicosis can be caused by transplacental immunoglobulin (TSI) transmission from a mother with Graves' disease.

## Clinical picture

It is caused by a **hypermetabolic state and activation of the sympathetic nervous system**

- warm, increased perfusion of the skin, excessive sweating, heat intolerance
- weight loss, accelerated growth
- GIT hypermotility and diarrhea
- **tachycardia**, palpitations, systolic hypertension, large pressure amplitude
- tremor, increased irritability
- thyroid myopathy - weakness of the proximal muscles of the limbs, up to 50% of patients
- exophthalmos (staring expression of the eyes) - caused by the increase of connective tissue due to autoimmune stimulation<sup>[3]</sup>,
- diffuse goiter
- nervousness, motor restlessness, concentration disorders, mood swings
- Graefe's symptom: looking down does not follow the bulbus cap,
- Stellwag symptom: decreased blinking frequency,
- Moebi's symptom: weakened convergence of bulbs.<sup>[2]</sup>

## Diagnostics

- Increased T3 and fT4 (the free form of thyroxine, is biologically active and responsible for the tissue effects of the hormone),
- reduced TSH,
- antibodies (against TSH-receptors (TRAK, TRAb, rTSH-ab), thyroglobulin, thyroid peroxidase),
- low serum cholesterol
- Ultrasound of the thyroid gland: volume determination, adenoma diagnosis (+ scintigraphy),
- bone age.<sup>[2]</sup>

## Diferencial diagnosis

- [Sepsis](#)
- [malignant hyperthermia](#)
- [post-transfusion reaction](#)
- [adrenal crisis](#)

## Treatment

1. **Inicial:**
  - thyrostatics (block T3 and T4 synthesis) - **thiamazole HVLP (Thyrozole), carbimazole** or **propylthiouracil**
  - [beta-blockers](#) (hyperkinetic circulation)
2. **Definitive:**
  - long-term treatment with thyrostatics
  - (sub)total thyroidectomy (after repeated relapses after discontinuation of thyrostatics)
  - radioiodulation of the thyroid gland by radioiodine ( surgical treatment preferred in the USA)

After TTE (total thyroidectomy) or destruction of the gland by radioactive iodine, the patient usually gradually switches to hypothyroidism with a lifelong need for **levothyroxine** replacement therapy.

## Neonatal hyperthyroidoism

- a rare life-threatening disorder
- etiology: transplacental transmission of maternal antibodies against the TSH receptor (TRAb, rTSH-ab) or unrecognized Graves-Basedow-type thyrotoxicosis,
- clinical picture in the fetus: intrauterine growth retardation, fetal tachycardia, acceleration of bone maturation, goiter, exophthalmos,
- clinical picture in untreated newborn: metabolic disruption, heart failure,
- therapy: conservative antithyroid treatment, gradual discontinuation within 2-3 months (maternal antibodies disappear from the circulation).<sup>[3]</sup>

## Links

### Related articles

- [Graves Basedow disease](#)
- [Hypothyroidism](#)
- [Examination and function of the thyroid gland](#)

### External links

- [Hypertyreóza and EKG \(TECHmED\)in czech](#)
- [Thyrotoxicosis in czech](#)

### Reference

1. HOLUB, V. Tyreotoxikóza. *Postgraduální medicína* [online]. 2003, roč. -, vol. -, s. -, dostupné také z <<https://zdravi.euro.cz/clanek/postgradualni-medicina/tyreotoxikoza-153007>>.
2. MUNTAU, Ania Carolina. *Pediatric*. 4. vydání. Praha : Grada, 2009. s. 77-78. ISBN 978-80-247-2525-3
3. LEBL, J, J JANDA a P POHUNEK, et al. *Klinická pediatrie*. 1. vydání. Galén, 2012. 698 s. s. 187. ISBN 978-80-7262-772-1.

### Used literature

- HAVRÁNEK, Jiří: *Tyreotoxická krize*.
- KUMAR, Vinay. *Robbins basic pathology*. 8. vydání. Philadelphia : Saunders/Elsevier, 2007. ISBN 978-0-8089-2366-4.
- PASTOR, Jan. *Langenbeck's medical web page* [online]. [cit. 2010-05-19]. <<https://langenbeck.webs.com/>>.