

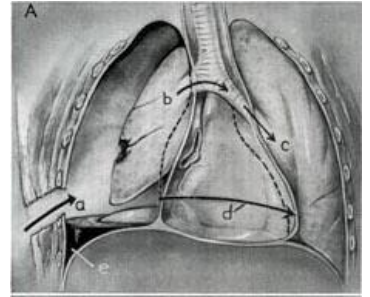
Hemothorax

The term **hemothorax** refers to the presence of blood in the pleural cavity.

Blood Sources

Bleeding may have a single etiology or may involve multiple factors.

1. rib fractures (approximately 100 ml from one rib),
2. intercostal artery trauma,
3. trauma of a. thoracica interna,
4. trauma of a. subclavia,
5. trauma of thoracic aorta, aneurysm rupture of thoracic aorta, hilar vascular trauma (rare).



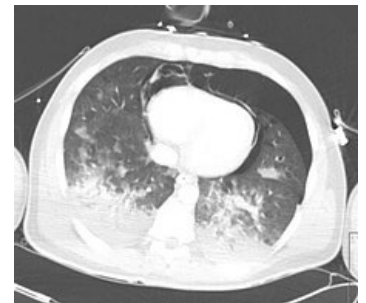Hemothorax.

Division of Hemothorax

1. **small** (up to 500 ml),
 2. **medium** (500–1500 ml),
 3. **large** (massive – over 1500 ml).
- Massive hemothorax is an immediately life-threatening condition - there's a risk of hypovolemia and shock, pulmonary oppression and malfunction of ventilation, often combined with pneumothorax.

Clinical Symptoms

1. shortness of breath,
2. cyanosis,
3. hypotension (a sign of shock in massive hemothorax),
4. weakened breathing and darkened percussion on the affected side, the jugular veins may have a higher filling (blockage of venous return) or, conversely, may be collapsed (in shock),
5. X-RAY shading of the pleural cavity with a wiped contour of the diaphragm and the upper edge higher laterally (smaller hemothorax may not be demonstrable in the supine position, imaging is better during standing - for massive hemothorax, blurring above half of the scapula indicates, fluid volume determination is more accurate at ultrasound).



Transverse CT scan after chest contusion. Pneumothorax, hemothorax, pneumomediastinum, pneumopericardium.

Treatment

- Punction, better drainage in the axillary midline in the 6th intercostal space at the upper edge of the lower rib:
 - waste up to *1000 ml* - bleeding usually stops spontaneously,
 - waste over *1500 ml* once or ongoing losses over 300ml/h - urgent **thoracotomy** with the treatment of the source of bleeding is indicated.
- In case of hypovolemia in massive hemothorax, it is necessary to infuse as soon as possible whole blood.
- Incomplete evacuation of the hemothorax results in pleural adhesions with limited respiratory movements, and hematoma infection causes empyema.

References

Related Articles

- Pleural Effusion
- Chylothorax
- Empyema
- Fibrothorax
- Pneumothorax

Source

- PASTOR, J. *Langenbeck's medical web page* [online]. [cit. 2009]. <<http://www.freewebs.com/langenbeck/>>.

