

# Pemphigoid

Pemphigoid has similar clinical manifestations as pemphigus, but blisters **are not determined by the acantholysis** and **are subepidermal**.

The prognosis is more favorable, treatment – corticosteroids and immunosuppressive drugs.

## Bullous pemphigoid

*Parapemphigus* or *senile pemphigus* is an autoimmune disease.

Most often occurs in older people (70–80 years old).

A reliable differentiation from the pemphigus is possible only with histological methods.

Blisters on slightly inflamed base, on limbs, later on the torso, symmetrical; leave pigmentation.

**Nikolsky's sign is negative.**

The course of the disease is prolonged, a spontaneous remission may also occur.

Sometimes it occurs as paraneoplasia or after drug treatment (penicillin, furosemide, Brufen...).

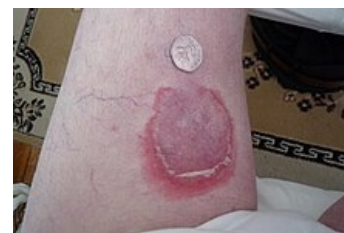## Benign mucosal pemphigoid

For *scarring pemphigus* is typical of the production of the IgG and IgA against BM with C3 deposits.

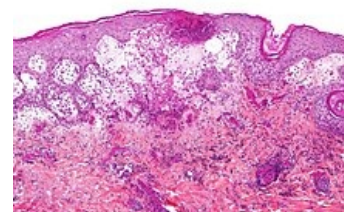
It affects the conjunctiva, nasal cavity, pharynx, larynx, nose, genitals, and anus.

**Heals with a scar**, if it affects the eyes it can cause blindness, leaving the stenosis.

Occurs rather in older individuals.



Bullous pemphigoid



Microscopic image of bullous pemphigoid

## Links

### Related articles

- Ocular cicatricial pemphigoid
- Pemphigus

### Source

- BENEŠ, Jiří. *Studijní materiály* [online]. [cit. 2010]. <<http://jirben.wz.cz>>.