

takes place is called the **sampling volume**. It usually has the shape of a drop, the length of which is variable and at the same time we can move it in the axis of the ultrasound beam to the required depth. The sample volume range and width may vary slightly in different types of ultrasound devices.

Color Doppler echocardiography

Assigns a certain color to a certain direction and speed of blood flow (red - blood towards the transducer, blue - from it). The relative flow rate is expressed by the shades of the respective color. The change of laminar flow into turbulent (stenosis, regurgitation) leads to the formation of a color mosaic with the possibility of quantification by regurgitation.

Indications: quantification of regurgitations (valve defects), identification + quantification of pathological short circuits (atrial or ventricular septal defect, myocardial rupture, fistula).

Around the mid-1980s, a qualitatively new Doppler method was developed - **color-coded real-time mapping** commonly referred to as **color Doppler**. The method uses the well-known principle of moving target indicator and autocorrelation of the transmitted and received phase of the ultrasonic wave. Under these circumstances, this is not a complete spectral analysis, but the mean velocity of the reflectors, especially erythrocytes, is recorded. The transmission of the ultrasonic waves takes place in a pulsed mode, in which the sampling of the **velocity takes place in several areas of the beam**, which is at the same time rapidly electronically deflected in the selected angular section. The obtained information is processed by a computer and, after conversion into a color code, superimposed on a two-dimensional echocardiogram of the amplitudes of the reflected echoes. The image is created in real time and records the time course of the flow and its changes in a given angular section. The number of sample volumes and lines varies according to the need and nature of the examination. Also, the display frequency (frames per second) varies depending on the number of lines in the sector.

The main advantage of color flow mapping is the spatial orientation of the velocity and direction of the prevailing flow over conventional DE. At the same time, the relationship between anatomical structures and flow direction stands out better; both information intersect and complement each other in the current two-dimensional echocardiographic and Doppler image.

Color imaging can also be superimposed on one-dimensional M-mode imaging.

A major limitation of the method is the ambiguity, which when the Nyquist limit is exceeded (which is lower than at continuous DE) leads to a change to red or vice versa. Therefore, the examiner's experience plays a very important role in the color Doppler examination. Of course, as with conventional Doppler systems, color mapping also depends on the correct settings of the instrument's controls. The sensitivity of the individual systems used so far also differs to some extent.

After reaching an international uniform agreement, the red color expresses the movement of blood towards the inverter and the blue color expresses the movement from it. The relative flow velocity (this is the "medium" velocity) is coded in shades of the respective color (from dark to lightest) and the variance of velocity, ie the expression of turbulent flow, is created by the admixture of green and yellow to the basic (red and blue). The result is a mosaic of all these colors.

There are some general rules for investigating color mapping of blood flow

- The narrower the color sector and the smaller the depth of the measurement, the more accurate and realistic the color display itself.
- The red color always indicates the flow towards the inverter, the blue from it.
- The lighter the color shade, the higher the flow rate of the reflectors.
- The mosaic of colors with a mixture of green and yellow indicates a greater variance of velocities, ie turbulence.

We consider information about to be the main benefit of color flow mapping

- direction and relative flow rate;
- uniformity or disruption of flow;
- the number and direction of the flow nozzles;
- timing of blood flows (along with M-mode imaging).

Doppler echocardiography methodology

Examination technique: Unlike conventional echocardiography, Doppler examination uses a slightly different scanning technique.

The following factors play a major role:

- tangential focusing of blood flow with the smallest possible incidence angle;
- the correct size and location of the sampling volume in the direction of the blood flow that we want to evaluate;
- optimal adjustment of the signal gain so that it is not amplified excessively and thus the signal-to-noise ratio deteriorates;

- selecting the Doppler converter with the most suitable transmission frequency; Roughly speaking, higher frequencies (5-7 MHz) are suitable for examining children and newborns, and lower frequencies (1-3 MHz) for adults. The higher the frequency, the greater the attenuation of the ultrasound energy as it passes through the tissues;
- selection of an appropriate examination window.

Perspectives of Doppler echocardiography

Color Doppler echocardiography

The method still has technical shortcomings in the current design. The ambiguity in the representation is generally considered to be one of the most serious. In the long run, the elimination of this disruptive, albeit experienced, shortcoming is expected.

Stress Doppler echocardiography

The technique is based on the principle of measuring changes in flow rate and quality during isotonic or isometric loading, or during interventional drug tests (dipyridamole). It is possible to evaluate both systolic and diastolic indicators of left and right ventricular function.

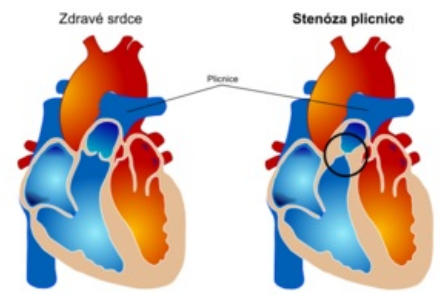
Perioperative Doppler echocardiography

It has a practical application. During cardiac surgery, perioperative determination of transprosthetic pressure gradients, detection of imperfectly removed or even newly formed regurgitations and assessment of ventricular function before disconnection from the extracorporeal circulation is possible. Technically, the examination of the exposed heart proves to be the easiest, because with the transesophageal approach it is often not possible to reach the optimal incidence angle during Doppler measurements.


Contrast echocardiography

It uses the echogenicity of air microbubbles in substances that are applied to the blood. After their i.v. application, it is possible to show their flow through the right and left heart.

Indications: pathological communications ([atrial septal defect](#)), highlighting of Doppler signals in patients, which are more difficult to examine, highlighting of an endocard silhouette (assessment of contractility disorders, determination of cardiac compartment volumes).



Pulmonary stenosis (left: healthy heart; right: pulmonary stenosis)



Transesophageal echocardiography

This article has been translated from WikiSkripta; ready for the **editor's review**.

Transesophageal echocardiography is an ultrasound examination of the heart, in which an ultrasound probe is inserted into the esophagus and stomach. The ultrasound probe thus comes in close proximity to the heart, which makes it possible to more accurately visualize some structures of the heart (compared to conventional transthoracic echocardiography).

The main indications for transesophageal echocardiography include:

- suspected presence of a dissecting aortic aneurysm, infectious endocarditis vegetation or thrombus in the atria;
- evaluation of valve prostheses;

- perioperative monitoring of left ventricular function

Links

Related Articles

- [Echocardiography](#)
- [Stress examination of the cardiovascular system](#)

Source

- [ws:Transezofageální echokardiografie](#)

References

1. ↑ CHILD, P., et al. *Internal Medicine*. 2nd edition. Prague: Galén, 2007. ISBN 978-80-7262-496-6 .



Links

Related Articles

- [Doppler echocardiography](#)
- [Stress examination of the cardiovascular system](#)

External links

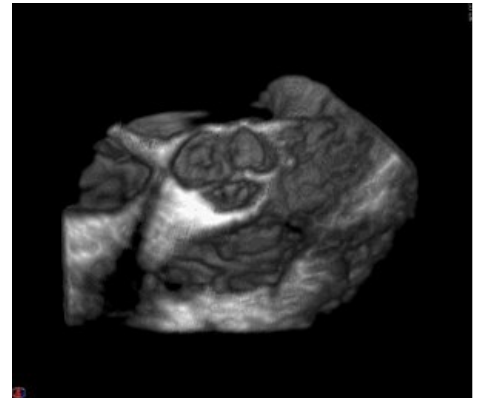
- Echocardiography - online free educational platform (TECHmED) (<https://www.techmed.sk/echo/projekcie/>)

References

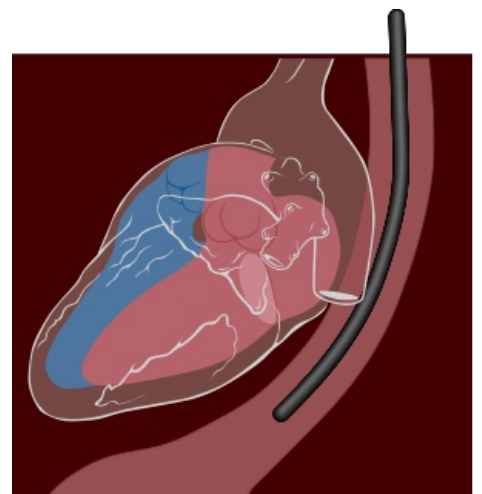
- CHILD, P., et al. *Internal medicine*. 2. edition. Prague : Galen, 2007. ISBN 978-80-7262-496-6.



probe for transesophageal echo



tricuspid valve imaging in 3d echocardiography



schematic of probe insertion