

# Compartment syndrome

**Compartment syndrome** is a set of symptoms arising from an increase in pressure in a closed anatomical space (compartment), which leads to vascular occlusions causing local ischemia.

- in this article, **compartment** is a space defined by the skeleton and the fascial coverings of muscles or intermuscular septa.

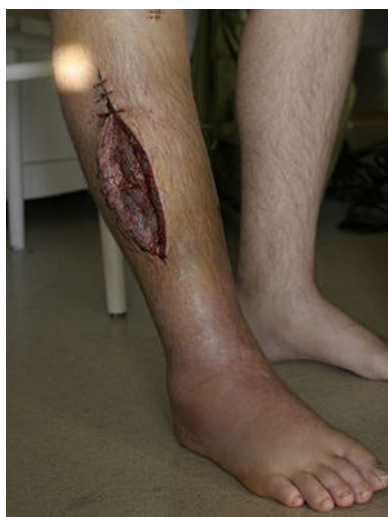## Pathophysiology of increased tissue pressure

- the physiological **pressure in the intrafascial space** is 3–5 mmHg
- the **perfusion pressure** is physiologically approximately 30 mmHg
- if the intrafascial pressure rises above 30-40 mmHg (in children the limit value is 30 mmHg – lower hypoxic resistance than in adults), **compartment syndrome** occurs.

In the compartment with increased intrafascial pressure, an **increase in venous pressure** first occurs. The vein walls have little resistance and collapse, decreasing the arterio-venous pressure gradient. It gradually decreases until the perfusion of the tissue stops and therefore its functions are impaired and eventually necrosis occurs. Due to blood stasis and impaired vascular permeability, **fluid moves from the vessels into the interstitium** (intrafascial space), where the pressure continues to increase – *circulus vitiosus* is created.

The length of time the increased pressure must be present for damage to occur varies. Irreversible changes occur during hypoxia:

- *nerves* – 2 hours,
- *muscles* – 6 hours.,
- *skin* – 8-12 hours.



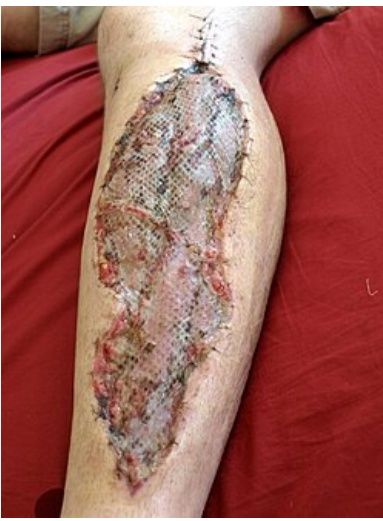## clinical symptoms of compartment syndrome

- **pain** in the affected area that worsens with muscle tension, elevation of the limb and does not respond to analgesics,
- **peripheral nerve disorders** (gradual development) – paresthesia, dysesthesia or anesthesia in the innervation areas of the nerves that pass through the given intrafascial space,
- **edema** of the periphery (fingers), discoloration and limited mobility, later edema of the entire limb,
- motor function disorder,
- the last stage is numbness and dysfunction of the entire affected area and the development of general ischemic muscle symptoms, which can lead to systemic symptoms, myoglobinuric renal failure and death.

**⚠ Attention! A preserved pulse on the periphery of the limb does not rule out compartment syndrome!!!**

## Consequences (irreversible changes)

1. sensory and motor disorders,
2. muscle contractures,
3. renal failure,
4. death.



## Localization of compartment syndrome

1. **limbs** – arm, forearm, hand, thigh, lower leg (most common location, 4 compartments), leg,
2. **abdomen** – increase in intra-abdominal pressure with limitation of diaphragm excursions and venous return,
3. **pelvis** – oliguria to anuria,
4. **chest**.

## Etiology

1. increased pressure inside the intrafascial space (bleeding, inflammation, burns, venous obstruction, etc.),
2. oppression of the intrafascial space from the outside (tight bandage, incorrect plaster fixation, skin scarring),
3. reduction of the volume of the intrafascial space (closure of the fascial defect, excessive pulling on the limb).
  - active young athletes may develop **chronic compartment syndrome** (increased muscle volume after exercise and increased hydrostatic pressure in capillaries with movement of intravascular fluid into the interstitium).

## Diagnosis of compartment syndrome

1. permanent awareness of the possibility of this serious complication,
2. the presence of a possible etiological factor,
3. clinical signs,
4. auxiliary examinations (oximetry, laboratory – creatine kinase, CRP, D-dimer and others),
5. permanent monitoring of intrafascial pressures - sovereign diagnostic method - piezoelectric sensors, introduced into the relevant intrafascial space.

## Differential diagnosis

- acute arterial occlusions (intrafascial pressure in the norm),
- arterial injury (arteriography, Doppler),
- primary nerve injury (disorder immediately after the injury and does not progress),
- Crush syndrome – long-term muscle compression, when washed out myoglobin clogs the distal tubules of the kidneys,
- other diseases – osteomyelitis, tendosynovitis, erysipelas, phlegmon (neuromuscular functions normal).

## Therapy

Therapy includes measures to reduce tissue pressure before irreversible ischemic changes occur (up to approximately 6 hours):

- removal of all possible precipitating causes, e.g. loosening plaster fixation of fractures,
- timely execution of fasciotomy,
- supportive pharmacotherapy (anti-infectives, anti-edematous treatment, enzyme therapy, vasodilation, analgesics, antiphlogistics, antihistamines).

**Fasciotomy** is always indicated if clinical symptoms develop and if there is an increase in pressure above 30-40 mmHg (in children above 30 mmHg). In the case of undeveloped clinical symptoms and pressure values at 20-30 mmHg, a conservative path is chosen with permanent pressure monitoring. If a developing compartment syndrome is suspected during the initial treatment of the fracture, a preventive fasciotomy can be performed.

## Volkmann's ischemic contracture

**Volkmann's ischemic contracture** is described as a complication of supracondylar humerus fracture in children.

## General characteristics

It is a type of **ischemic contracture of the forearm**. It usually arises from an injury of the a. brachialis, which is related to an extensor dislocated **supracondylar** fracture of the humerus, from the pressure of loading a tight circular cast. However, it can also occur in other types of injuries - forearm fractures, soft tissue injuries, etc. The pathophysiological basis is that there is ischemia of the volar muscles of the forearm. If the condition persists for more than 24 hours, necrosis of the muscles and their replacement by connective tissue with subsequent loss of function occurs. In severe cases, the fingers become claw-like and become afunctional.

## Clinical picture

The pathogenesis is contracture resulting from **inadequate arterial perfusion and venostasis**. All this leads to ischemic **degeneration of the muscles**. The infarct has an ellipsoidal shape and is located in the area along the course of the a. interossea communis. On the basis of healing of the ischemic parts by scarring, the m. flexor digitorum superficialis et profundus begin to contract and the **flexion of the wrist and clawed position of the fingers** of the hand develop. In addition, paresis of the n. ulnaris et medianus is added, which leads to the metacarpophalangeal joint then being in flexion and the interphalangeal joints in extension (or vice versa).

## Prevention

**Early treatment** of the fracture (conservative repositioning and percutaneous fixation) and **comprehensive monitoring** of the limb condition.

## Links

### Related articles

- [Compartment syndrome](#)
- [Fractures of the distal end of the humerus](#)
- Sudeck's algodystrophic syndrome

### Reference

- PASTOR, Jan. *Langenbeck's medical web page* [online]. [cit. 2009]. <<https://langenbeck.webs.com/>>.

## Abdominal compartment syndrome

- it is caused by an increase in intra-abdominal pressure above 25 mmHg
- **causes**: accidental or spontaneous [intra-abdominal bleeding](#), [aortic aneurysm rupture](#), [ascites](#), acute pankreatitis, intra-abdominal tamponade during surgery, closure of the abdominal wall under tension, etc.
- **clinical symptoms** (influence of individual organ systems):
  1. **respiratory** - elevation of the diaphragm, respiratory insufficiency,
  2. **cardiovascular** - increase in [central venous pressure](#), [decrease in cardiac output](#),
  3. **abdominal** - increase in abdominal girth, decrease in blood flow to the splanchnic,
  4. **renal** - oliguria (earliest symptom),
- intra-abdominal pressure monitoring with a catheter inserted into the bladder (or into the stomach or into the vena cava inf.),
- **treatment** decompression laparotomy (indicated by intra-abdominal pressure above 25 mmHg with simultaneous oliguria), immediately after opening the abdominal cavity, an infusion of [mannitol](#) with bicarbonate is given (prevention of asystole due to the effect of released acidic metabolites during reperfusion), then temporary closure of the abdominal cavity (Ethizip).

## Summary video

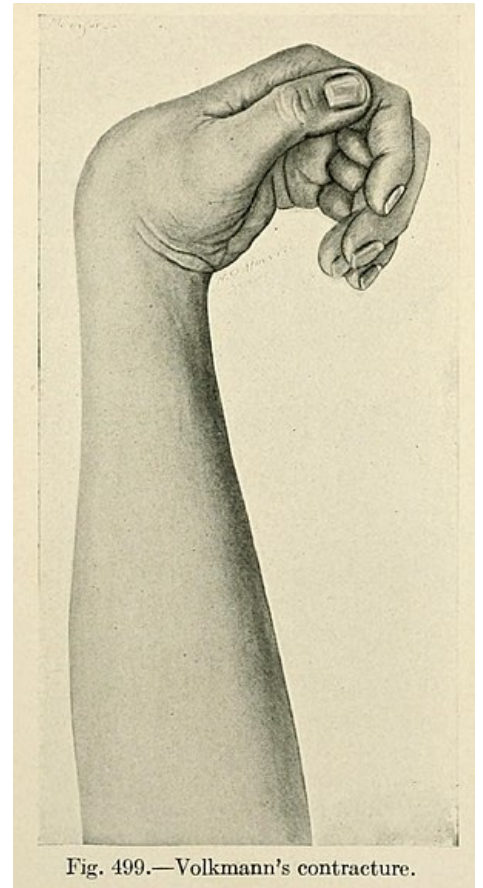



Fig. 499.—Volkmann's contracture.

Volkmann's contracture



## Links

### Related articles

- [Compartment syndrome of the lower leg](#)
- [Crush syndrome](#)

### Source

- PASTOR, Jan. *Langenbeck's medical web page* [online]. [cit. 2010]. <<https://langenbeck.webs.com/>>.