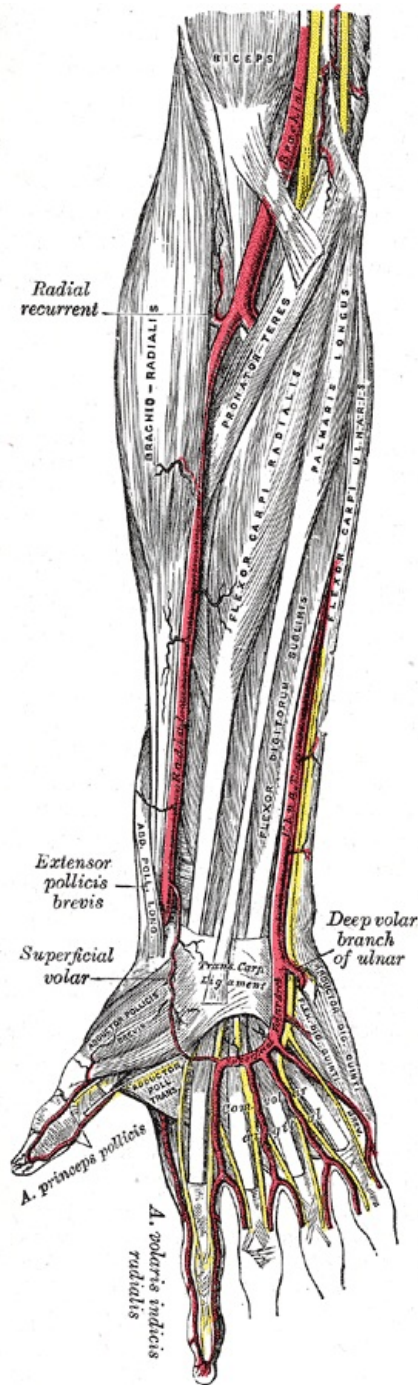


Radial artery

radial artery

spindle artery



Arteries of the forearm

THE	A12.2.09.027
Resigns from	a. brachialis
Branches	a. recurrent radialis, a. nutricia radii, r. carpalis palmaris, r. palmaris superficialis, r. carpalis dorsalis, a. princeps pollicis, a. radialis indicis, arcus palmaris profundus

Radial artery descends from the division of the *brachialis artery* in the elbow area on the radial side. Her pulse is palpable on the wrist between the *brachioradialis* muscle and the *flexor carpi radialis* muscle. It is found in the *foveola radialis*. After crossing the carpus, it runs to the dorsal part of the hand, where it enters *Guiot's space* between the heads of the *interosseus dorsalis primus* muscle and forms the *arcus palmaris profundus*.

Gives off **r. palmaris superficialis** participating in arcus palmaris superficialis , branches for *rete carpi palmare* and *dorsale* and **a. princeps pollicis** . It supplies the muscles of the anterior and lateral groups and the skin of the lateral half of the forearm. It contributes to the supply of the palm, the back of the hand and the fingers.

Links

Reference

1. CIHÁK, Radomír. *Anatomy 3*. 2nd ed. Prague: Grada Publishing, 2004. 692 pp. ISBN 978-80-247-1132-4 .
2. ↑ HOLEK, Martin. *Anatomy of the limbs for the winter autopsy [electronic resource]: (non-saleable script for first-year students of the 3rd LF UK)*. 1st edition. Prague: Charles University, 3rd Faculty of Medicine, 2009. ISBN 978-80-254-3223-5 .

Kategorie:Anatomie Kategorie:Angiologie