

Ventricular fibrillation

Ventricular fibrillation (VF) and rapid ventricular tachycardia (VT) belong to the so-called malignant arrhythmias. These are heart rhythm disorders that urgently threaten the patient's life (they must be dealt with immediately) and are the most common cause of sudden cardiac death (NSS).^[1] Ventricular fibrillation occurs relatively often as part of an acute myocardial infarction.

File:Heart of ventricular fibrillation.png

Scheme of chaotically arising excitations in the myocardium of the heart chambers during ventricular fibrillation.

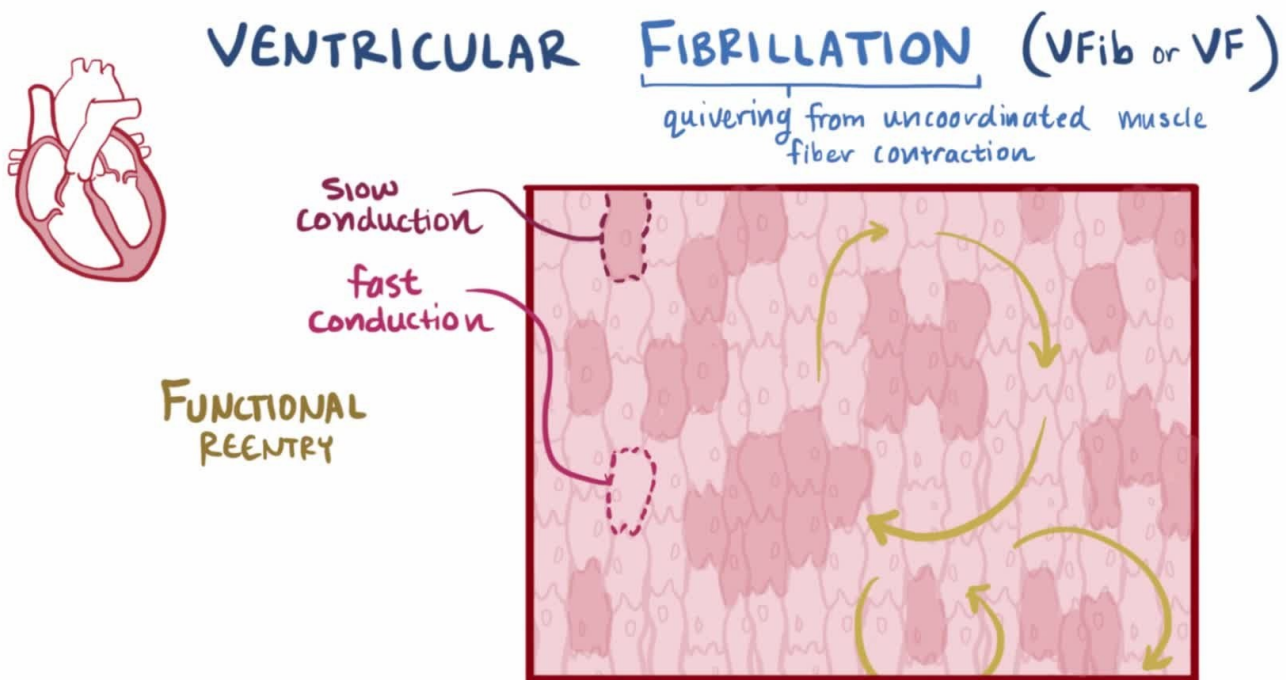
Etiology

The causes of ventricular fibrillation include:^{[1] [2]}

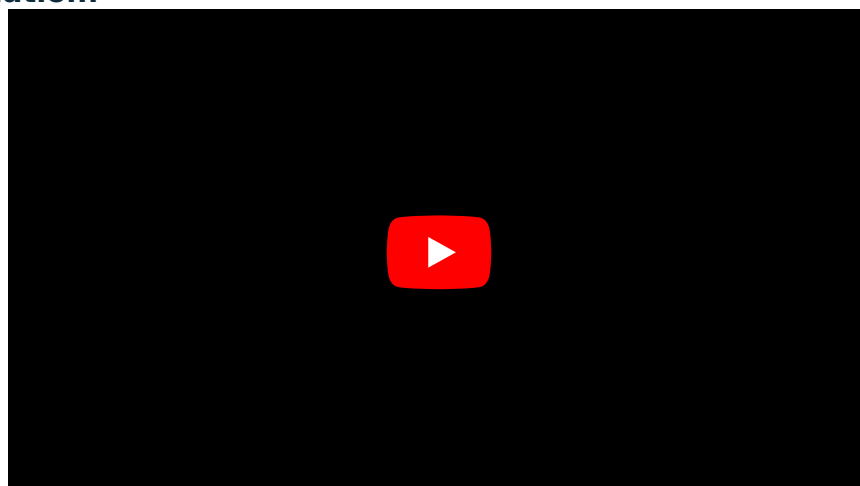
- Organic heart disease (**CHD** and **MI**, cardiomyopathy, cardiac amyloidosis, ...),
- long QT syndrome (LQTS), Brugada syndrome,
- idiopathic ventricular fibrillation.

Pathogenesis

In the case of ventricular fibrillation, the individual cardiomyocytes of the heart chambers contract completely **unsynchronized**. **These chaotic and rapid contractions lead to a complete failure of the heart's function as a pump**. Since the heart is not pumping any blood (minute cardiac output is almost zero), there is severe **perfusion failure** of vital organs including the cerebrum (→ loss of consciousness occurs within 10 s) and without immediate cardiopulmonary resuscitation and defibrillation, ventricular fibrillation leads to death (irreversible brain damage develops in 3-5 minutes^[3]).



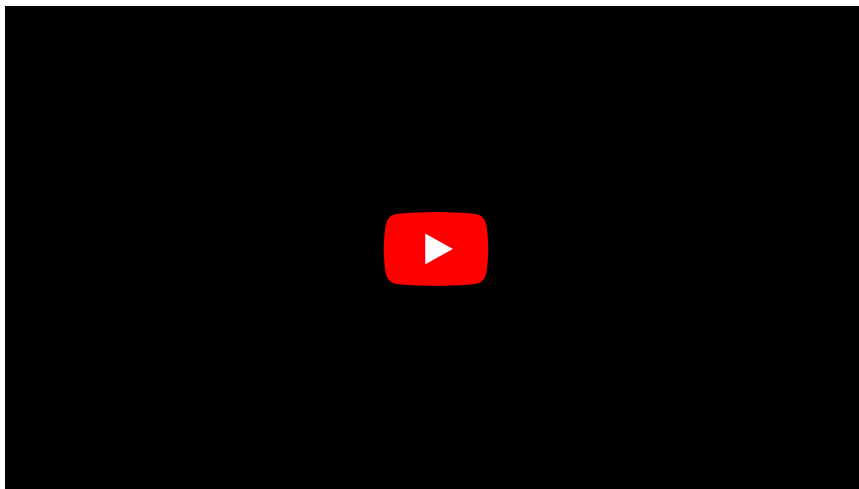
Ventricular fibrillation:



Ventricular flutter:



Ventricular flutter 2:



Physiologically, a depolarization wave occurs in the SA node. In ventricular fibrillation, '*abnormal electrical impulses* occur directly in the heart's chambers. These abnormal impulses can arise unifocally or multifocally, it can be a reentry mechanism or a combination of these mechanisms.

Ventricular tachycardia, ventricular flutter or early ventricular extrasystole can become ventricular fibrillation.

Clinical manifestation


Clinically, ventricular fibrillation manifests as:^[2]

- loss of consciousness;
- inaudible heart sounds;
- non-palpable pulse;
- immeasurable pressure.

Diagnostics

The diagnosis is based on the *ECG*.

Individual cardiomyocytes contract completely independently and unsynchronized, therefore we cannot identify any QRS complexes on the ECG. We see irregular waves with a frequency of 300/min and more.



Ventricular fibrillation - scheme.

File:Lead II rhythm generated ventricular fibrillation VF.JPG

ECG image of ventricular fibrillation.

Treatment


- Treatment consists of immediate initiation of **cardiopulmonary resuscitation'' (opinions on precordial beat vary) and external or internal defibrillation** as soon as possible.
- Some types of ventricular fibrillation can be treated with **radiofrequency ablation'** of focal ventricular

ectopy.^[1]

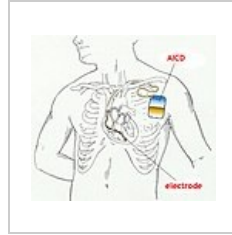
- In primary and secondary prevention, some antiarrhythmic drugs and implantation of an implantable cardioverter-defibrillator (ICD) can be used.



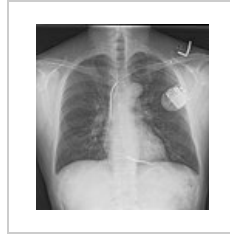Portable manual external defibrillator



Implantable cardioverter-defibrillator



Scheme of the established ICD



X-ray image of an implanted ICD

Links

Related Articles

- [Defibrillation](#)
- [Atrial fibrillation](#)
- [Antiarrhythmics](#)
- [Cardiac conduction system](#)

External links

- [Ventricular fibrillation and ECG \(https://www.ecgbook.com/ventricular-fibrillation/\)](https://www.ecgbook.com/ventricular-fibrillation/) - Free ECG book

References

- MLČOCHOVA, Hanka, et al. Catheter ablation of ventricular fibrillation by elimination of triggering ventricular ectopy. *Interv Akut Kardiol* [online] . 2007, year 5, vol. 5, pp. 173-176, also available from <<http://www.solen.cz/pdfs/kar/2007/05/02.pdf>>. ISSN 1803-5302.
- HAMAN, Peter. EKG Learning Website : EKG Basics [online]. [feeling. 2010-11-21]. <<http://www.ekg.kvalitne.cz/tvorba.htm#Fibrillation%20komor>>.
- ČESKA, Richard, et al. Internal 1st edition. Prague: Triton, 2010. 855 pp. pp. 480-481. ISBN 978-80-7387-423-0.

References

- HAMPTON, John R. *EKG Concise, Clear, Clear*. 6th edition. Grada, 2005. 149 pp. ISBN 80-247-0960-0 .
 - HAMAN, Peter. *EKG Learning Website : EKG Basics* [online]. [feeling. 2010-11-19]. <<http://www.ekg.kvalitne.cz/tvorba.htm#Fibrillace%20komor>>.
 - HELLO, Robert. Cardiology ring. III. internal clinic of VFN and 1st Faculty of Medicine of the University of Prague in Prague, 2009.
 - VILIKUS, Zdeněk. Interpretation of ECG at rest and during exercise. Institute of Physical Education Medicine 1. LF UK and VFN; 2010.
1. MLČOCHOVÁ, Hank. , et al. Catheter ablation of ventricular fibrillation using elimination of triggering ventricular ectopy. *Interv Akut Kardiol* [online]. 2007, y. 5, vol. 5, p. 173-176, Available from <<http://www.solen.cz/pdfs/kar/2007/05/02.pdf>>. ISSN 1803-5302.
 2. HAMAN, Peter. *EKG Learning Site : ECG Basics* [online]. [cit. 2010-11-21]. <<http://www.ekg.kvalitne.cz/tvorba.htm#Fibrillation%20komor>>.
 3. CZECH, Richard, et al. *Intern*. 1. edition. Prague : Triton, 2010. 855 pp. pp. 480-481. ISBN 978-80-7387-423-0.