

Foramen ischiadicum majus

The **foramen sciaticum majus** is the opening leading from the pelvis between the ligamentum sacrotuberale (dorsal and medial boundaries), **the ligamentum sacrospinale** (caudal boundaries) and the *incisura ischiadica major ossis coxae* (ventral and lateral boundaries).

Passing through:

- *piriformis muscle*, which divides the area into two parts: foramen suprapiriforme, *foramen infrapiriforme*.

/

Related Articles

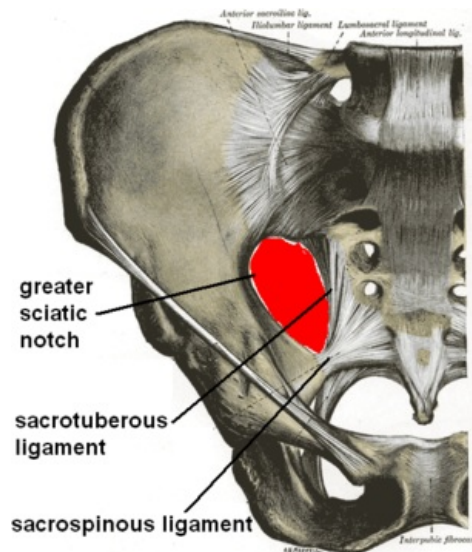
Related Articles

- [Foramen ischiadicum minus](#)
- pelvic bone

Bibliography

- GRIM, Miloš a Rastislav DRUGA. *Základy anatomie. 5., Anatomie krajín těla.* 1. vydání. Praha : Galén : Karolinum, 2002. 119 s. ISBN 80-7262-179-3.
-

Kategorie:Anatomie Kategorie:Topografická anatomie



Foramen ischiadicum majus, pelvic view

Media boundaries	leaque. sacrotuberale
Lateral boundaries	Incisura ischiadica major ossis coxae
Border dorsally	leaque. sacrotuberale
Border ventrally	Incisura ischiadica major ossis coxae
Caudal border	leaque. sacrospinale
Builds on	pelvic space
Content	m. piriformis, foramen suprapiriforme, foramen infrapiriforme