

# Deep Vein Thrombosis

## Under construction / Forgotten

**This article was marked by its author as *Under construction*, but the last edit is older than 30 days.** If you want to edit this page, please try to contact its author first (you will find him in the history ([https://www.wikilectures.eu/index.php?title=Deep\\_Vein\\_Thrombosis&action=history](https://www.wikilectures.eu/index.php?title=Deep_Vein_Thrombosis&action=history))). Watch the page as well. If the author will not continue in work, remove the template `{{Under construction}}` and the page.

Last update: Monday, 08 Dec 2014 at 5.06 pm.

Deep vein thrombosis is the most often cause of pulmonary embolism. Thrombosis is localized in deep vein system of lower limb (but the same type of thrombosis can be localized in deep vein system of upper limb). Typical localization is deep vein of lower leg, popliteal vein, femoral vein, iliac vein.

## Pathophysiology

Virchow's triad:

- endothelial dysfunction,
- blood flow deceleration,
- blood hyperviscosity (change in the composition of blood).

There is an equilibrium in blood clotting in common situation. For thrombus formation is necessary impulse.

## High Risk Patient

We have several groups of patients with high risk of thrombus formation:

- **patients with inborn risk:**
  - protein C or protein S deficiency
  - Leiden's mutation
  - elevated level of clotting factors (II, ...)
- **patients with acquired risk:**
  - immobilization
  - surgery (abdominal surgery, oncosurgery, orthopedics - total endoprosthesis)
  - trauma
  - hormonal contraception
  - infection
  - central vein catheter (typically in subclavian artery)
  - pregnancy - especially the 2<sup>nd</sup> and 3<sup>rd</sup> trimester (because of physiological elevation of clotting factors)
  - postpartum period

## Diagnostic

### Symptoms

- pain - painful palpation, painful dorsiflexion of foot (Homans sign)
- edema - because of decreased vein blood drainage, greater limb circumference
- peripheral (superficial) vein dilatation - because of decreased vein blood drainage, superficial veins must take greater amount of blood
- peripheral pulsation can not disappear just only because of deep vein thrombosis, there must be affected arteries

## Diagnostic Methods

- laboratory:
  - elevated D-dimers - thrombolysis marker
- duplex sonography - basic noninvasive method
- venography - with contrast agent
- CT angiography - in suspected iliac vein thrombosis

## Therapy

- **anticoagulation:**
  - **LMWH** - works immediately, preferred in pregnancy and short time therapy (acquired risk - surgery ...), e.g.

fraxiparine, enoxaparine.

- **heparin** - is less performed, just in patients with contraindicated LMWH or in patient suspected on pulmonary embolism
- **warfarin** - peroral anticoagulant, unfortunately it takes several days (3-6) before in really starts work, but the patient should have specific therapy immediately (start with warfarin and LMWH in the same time and stop with LMWH in 4-5 days). This drug should be performed in patients with inborn high risk of thrombosis. Needed INR level is 2-3.
- **thrombolysis** - is an extensive method in patients with high iliac vein thrombosis, these patients are in high risk of pulmonary embolisation.

## Prevention

- soon mobilization of patients (after surgery)
- bandage of limbs
- LMWH before surgery

## Complications

- pulmonary embolization
- deep vein valves dysfunction
- deep vein system hypertension → vein insufficiency

## Links

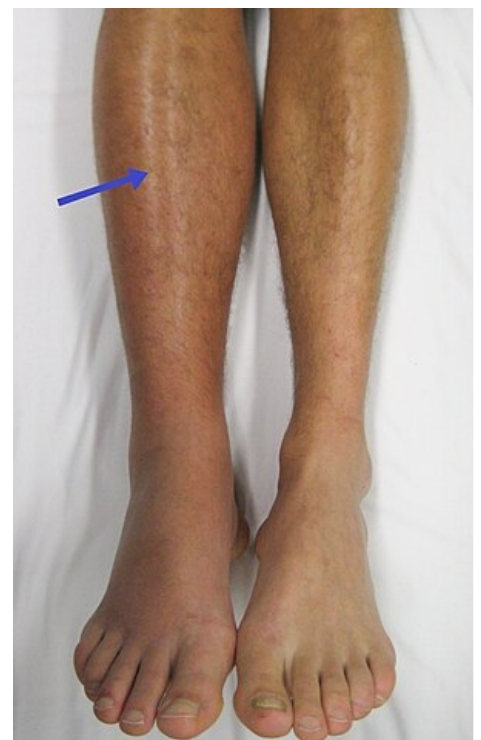### Related articles

- Pulmonary Embolism

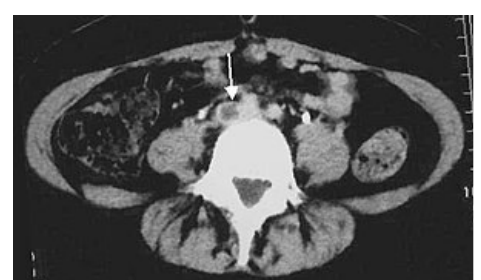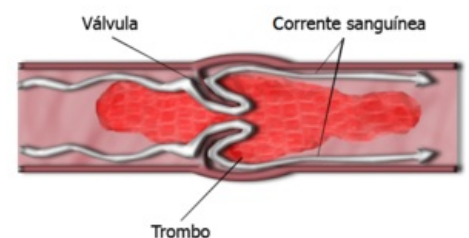
## References

## Bibliography

## Further reading



Lower limb edema.



CT, thrombus of iliac right vein.